

Carnicom Institute Research

2019

Acknowledgements

Mission Statement:

Carnicom Institute is a non-profit organization working solely for the benefit of humanity. Our goal is to provide the public with beneficial and responsible information through scientific, educational, environmental, and health research for the public welfare. The Institute has devoted significant effort to the important issues of geoengineering and bioengineering.

Disclaimer:

The Carnicom Institute is a non-profit health and environmental educational and research organization serving the public welfare. CI is not a clinic and does not perform any medical diagnosis, medical treatment, or prescription of therapy. We do not advocate any proprietary products, protocols, or therapies. All studies conducted by the Institute are for research purposes only. Our purpose is to provide information and education to the public.

License:

Carnicom Institute by is licensed under a Creative Commons Attribution-NonCommercial-NoDerivatives 4.0 International License. <https://creativecommons.org/licenses/by-nc-nd/4.0>

Table of Contents

Mar		1
	Carnicom Foundation Proposal & Summary	1
Apr		4
	CI Migrates in the Name of Free Speech	4
May		6
	Morgellons Toxicity - A Continued Report	6
Jun		8
	Santa Fe Conference - 2019 - Presentation Notes	8
	Morgellons: The Evidence is Evident	11
Jul		18
	Santa Fe Conference 2019	18
	Simple Observations, Important Conclusions	19
	Complex Observations, Unknown Consequences	28
Nov		36
	The Transformation of a Species?	36

Mar Carnicom Foundation Proposal & Summary

Mar 31, 2019

Carnicom Foundation Proposal & Summary

Carnicom Institute is seeking to establish a non-profit educational foundation by the name of [Carnicom Foundation](#). Carnicom Foundation will carry the legacy of Carnicom Institute research forward to serve the public environmental and health interests for current and future generations.

Carnicom Institute is expressly appealing to the philanthropic members of society who have a humanitarian commitment to the environment and to the welfare, rights, and health of the world population.

[Funding campaigns](#) have been established to initiate the creation of the [Carnicom Foundation](#). The individual description for each campaign [is available](#) on this website.

The existing core campaign fund list is shown immediately below.

Existing Campaign Funds:

DNA & Protein Laboratory Analysis Fund

Website & Internet Systems Fund

Research Custody & Protection Fund

Carnicom Foundation Legal Fund

Community Health Professional Network Fund

The Story of Carnicom Institute – Book Fund

Professional Recruitment Fund

Print & Digital Library Fund

Nuclear Magnetic Resonance (NMR) Fund

Core Funding Estimate Total ~\$300K

Numerous additional or expanded aspects of the proposed Carnicom Foundation will need to be developed to fulfill the mission of Carnicom Foundation. The list below will outline some of these important needs.

Therefore, in summary and in brief, the list is as follows:

Foundation Education & Research Facility:

Building Facility

Public Liaison/Secretary Staffing

External Research Coordination

Contract Laboratory Services

In-House Research Staff

Community Health Professional Network Development

Health & Medical Advocacy (e.g., clinical trials, animal trials)

Institutional Review Board (IRB) Restoration

Intellectual Property Division

Prospective Commercial Developments

Expansion of Health & Environmental Research Scope

Fund Raising Services

Marketing Division

Conference Division

Accounting Services

Legal Representation

Digital & Print Library Services

Abstract Authoring & Indexing of Research Materials

Documentary Development

Preservation & Protection of Additional Studies (e.g., mathematical intellectual property)

It is not essential to outline the budget for this expansion at this time; the resources required are obviously significant.

If you have an interest in [supporting](#) any aspect of Carnicom Institute and the future [Carnicom Foundation](#), please contact us at info@carnicominstitute.org.

You may also contact CI by mail at:

Carnicom Institute
PO Box 1224
Monticello, UT 84535

With best regards,

Clifford E Carnicom
President, Carnicom Institute



Apr
CI Migrates in the Name of Free Speech

Apr 23, 2019

CARNICOM INSTITUTE MIGRATES IN THE NAME OF FREE SPEECH

Clifford E Carnicom

Apr 23 2019

Due to the censorship, propaganda, and surveillance by both Google and Facebook, Carnicom Institute is departing in protest from these platforms to alternative venues that openly advocate free expression and disclosure of information. You may also find these separation statements on the CI YouTube and Facebook pages.

Carnicom Institute condemns the levels of infringement and intrusion that are in place at both YouTube and Facebook.



[Carnicom Institute YouTube Channel](https://www.youtube.com/c/CarnicomInstitute)

(<https://www.youtube.com/c/CarnicomInstitute>)

The media content of CI is now to be found at:



[Carnicom Institute at Archive.org](https://archive.org/details/@carnicominstitute)

<https://archive.org/details/@carnicominstitute>

The social content of CI is now to be found at:



[Carnicom Institute at MeWe.com](https://mewe.com/join/carnicominstitute)

(<https://mewe.com/join/carnicominstitute>)



[Carnicom Institute at Facebook](https://www.facebook.com/carnicominstitute/)

(<https://www.facebook.com/carnicominstitute/>)

May **Morgellons Toxicity - A Continued Report**

May 21, 2019

Morgellons Toxicity – A Continued Report

by

Clifford E Carnicom

May 21 2019

(Note : Higher Bandwidth Required – Videos)

This is the third in a series of reports that reveal serious toxicity issues that are a consequence of the microbiology that is known to be causal to the “Morgellons” health condition.

The first of these reports is a series of papers that examine this toxicity and its damaging effects upon certain plant, fungal and agricultural examples. The second report examines this toxicity within an example of primal life on this planet, the protozoa. This third report examines this microbe toxicity on a more elevated life form, the crustacean (Artemia).

In all cases, the toxicity is apparent, profound, and of great consequence with implications for the life on this planet.

The source of the toxin is a water soluble protein that has been isolated and extracted from the microbe of concern, designated by this researcher as a “*cross-domain*” bacteria. This tentative designation remains in place based upon numerous papers on this site to justify that claim. Additional proteins of different form and bio-molecules have also been isolated from this same microbe, including DNA.

https://carnicom institute.org/wp/wp-content/uploads/2019/05/Normal_01_x264.mp4

Video of Brine Shrimp Control Solution – Trial 1

Brine Solution Only – No Protein Added

https://carnicom institute.org/wp/wp-content/uploads/2019/05/Treated_01-1_x264.mp4

Video of Brine Shrimp Subjected to CDB Microbial Protein – Trial 1

Brine Solution with Addition of Microbial Protein – 1 Hour into Treatment Period

Concentration of Protein Solution : Approx. 0.1% (1 part in 1000)

Magnification : Approx. 16x

https://carnicom institute.org/wp/wp-content/uploads/2019/05/Treated_01-2_x264.mp4

Video of Brine Shrimp Subjected to CDB Microbial Protein – Trial 1

Brine Solution with Addition of Microbial Protein – 2 Hours into Treatment Period

Concentration of Protein Solution : Approx. 0.1% (1 part in 1000)

Magnification : Approx. 16x

https://carnicom institute.org/wp/wp-content/uploads/2019/05/Normal_02_x264.mp4

Video of Brine Shrimp Control Solution – Trial 2
Brine Solution Only – No Protein Added

https://carnicominstitute.org/wp/wp-content/uploads/2019/05/Treated_02-01_x264.mp4

Video of Brine Shrimp Subjected to CDB Microbial Protein – Trial 2
Brine Solution with Addition of Microbial Protein – 30 Minutes into Treatment Period
Concentration of Protein Solution : Approx. 0.5% (5 parts per 1000)
Magnification : Approx. 16x

https://carnicominstitute.org/wp/wp-content/uploads/2019/05/Treated_02-02_x264.mp4

Video of Brine Shrimp Subjected to CDB Microbial Protein – Trial 2
Brine Solution with Addition of Microbial Protein – 1 Hour into Treatment Period
Concentration of Protein Solution : Approx. 0.5% (5 parts per 1000)
Magnification : Approx. 16x

The motility and functioning of the brine shrimp continues to decline over time with an end result of death.

The evidence provided by these videos, as well as all information provided within the previous toxicology reports, speaks for itself as to the seriousness of the issues involved here. The evidence is now strong that all life on earth is affected by this “*New Biology*” ([Jan, 2014](#)). It remains a remarkable state of affairs that many of those of means and influence to assist the general welfare continue to turn a deaf ear and blind eye to the environmental and biological transformations that are in progress on this planet. This is especially enigmatic when the existence of the human species is, at a minimum, jeopardized but also most likely threatened to some degree by this same neglect. It is understood that such avoidance can result from both ignorance and fear, but this does not dismiss the realities and responsibilities that lie before us.

Sincerely,

Clifford E Carnicom
May 19, 2019

Jun

Santa Fe Conference - 2019 - Presentation Notes

Jun 6, 2019

Santa Fe Conference
GeoEngineering & BioEngineering:
The Unmistakable Link
Presentation Notes
April 27-28, 2019

[Download Presentation Notes Here – PDF File](#)



“CARNICOM INSTITUTE : PAST, PRESENT & FUTURE”

Clifford E Carnicom
President, Carnicom Institute

BioEngineering & GeoEngineering : The Unmistakable Link
April 27 - 28, 2019
Santa Fe, NM

[Download Presentation Notes Here – PDF File](#)

Additional Supporting Information for the Conference Presentation:

PAST

DNA & The New Biology

<https://carnicominstitute.org/wp/cdb-growth-progressions/>

<https://carnicominstitute.org/wp/cross-domain-bacteria-isolation/>

<https://carnicominstitute.org/wp/dna-isolated/>

<https://carnicominstitute.org/wp/the-new-biology/>

Morgellons

<https://carnicom institute.org/wp/morgellons-an-environmental-source/>
<https://carnicom institute.org/wp/morgellons-first-observations/>Electromagnetics & Biology
<https://carnicom institute.org/wp/extraordinary-biological-observations/>
<https://carnicom institute.org/wp/positive-elf-spectrum-identification/>Initial Problems & Social
Ramifications
<https://carnicom institute.org/wp/epa-refuses-to-identify-returns-sample-18-month-delay/>
<https://carnicom institute.org/wp/biological-components-identified/>
<https://carnicom institute.org/wp/ground-sample-sent-certified-mail-to-epa/>
<https://carnicom institute.org/wp/visitors-to-www-carnicom-com/>
<https://carnicom institute.org/wp/a-classic-progression-series-over-santa-fe/>

Cloud in a Bottle

<https://www.youtube.com/watch?v=MBh6TPYH3XU>

Mass Extinction – Annihilation

<https://www.youtube.com/watch?v=kWrPo02e4fo>
<https://www.nationalgeographic.com/animals/2019/02/why-insect-populations-are-plummeting-and-why-it-matters/>
<https://www.theguardian.com/environment/2019/feb/10/plummeting-insect-numbers-threaten-collapse-of-nature>
<https://www.pnas.org/content/114/30/E6089>

PRESENT**PLANT TOXICOLOGY STUDIES**

<https://carnicom institute.org/wp/mustard-seed-germination-initial-report/>
<https://carnicom institute.org/wp/yeast-deformation-initial-report/>
<https://carnicom institute.org/wp/mustard-seed-germination-initial-report/>
<https://carnicom institute.org/wp/bean-growth-report/>
<https://carnicom institute.org/wp/a-toxicology-study/>
<https://carnicom institute.org/wp/another-marker-for-examination/>
<https://carnicom institute.org/wp/global-validation/>
<https://carnicom institute.org/wp/morgellons-research-project-primary-symptoms-survey-results/>
<https://carnicom institute.org/wp/unique-protein-isolated-characterized/>
<https://carnicom institute.org/wp/morgellons-international-presence/>
<https://carnicom institute.org/wp/a-clash-of-evidence/>

Full Research Listing:

<https://carnicom institute.org/wp/research-library-listing/>Additional videos:

[Preview YouTube video Making a Cloud in a Bottle](#)



[Preview YouTube video The Sixth Extinction](#)

FUTURE

https://www.flipcause.com/secure/cause_pdetails/NDYzOTE=

This link will take you to the campaigns that form the outline of the proposed transition from Carnicom Institute toward Carnicom Foundation.

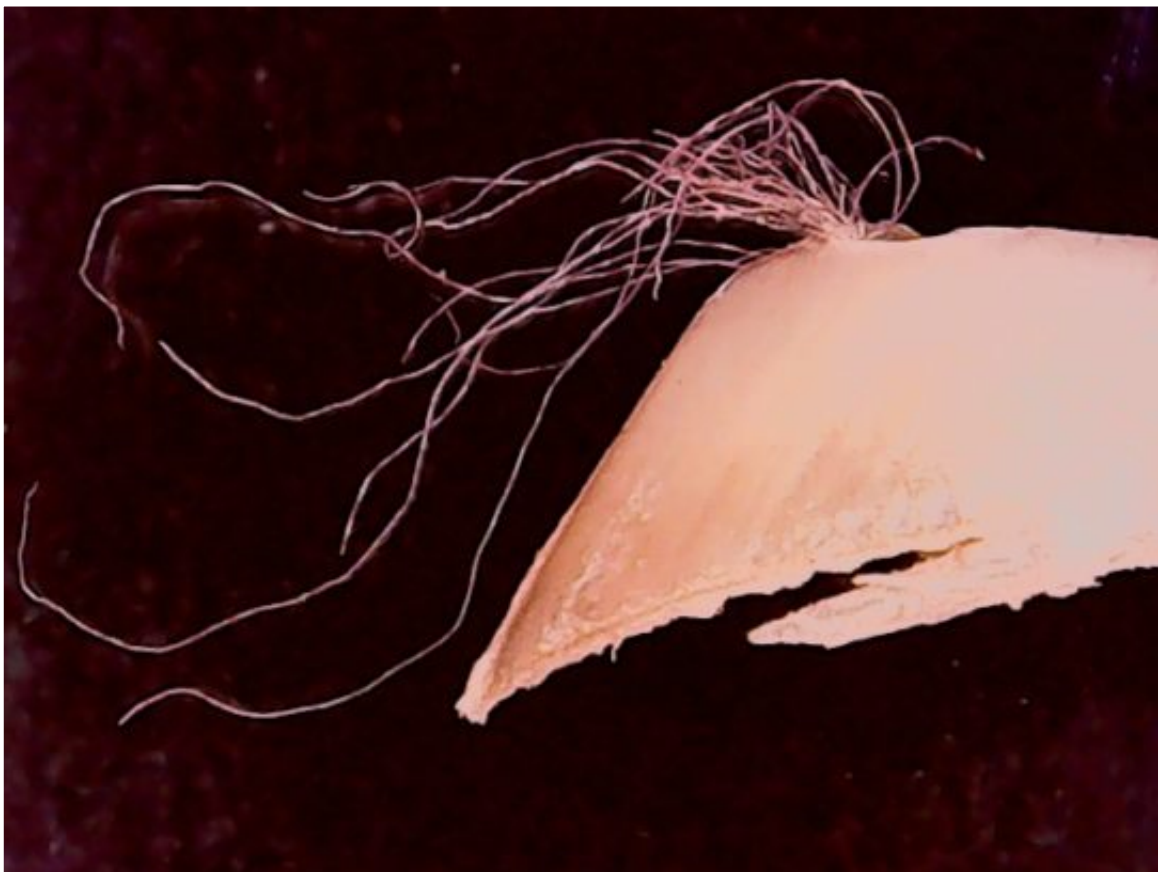Morgellons: The Evidence is Evident

Jun 13, 2019

**Morgellons:
The Evidence is Evident**
by
Clifford E Carnicom
Jun 13 2019

What follows below is both striking and indisputable. An individual who is affected by the characteristic external symptoms of the Morgellons condition has submitted a sample for observation that is incontrovertible as to its uniqueness.

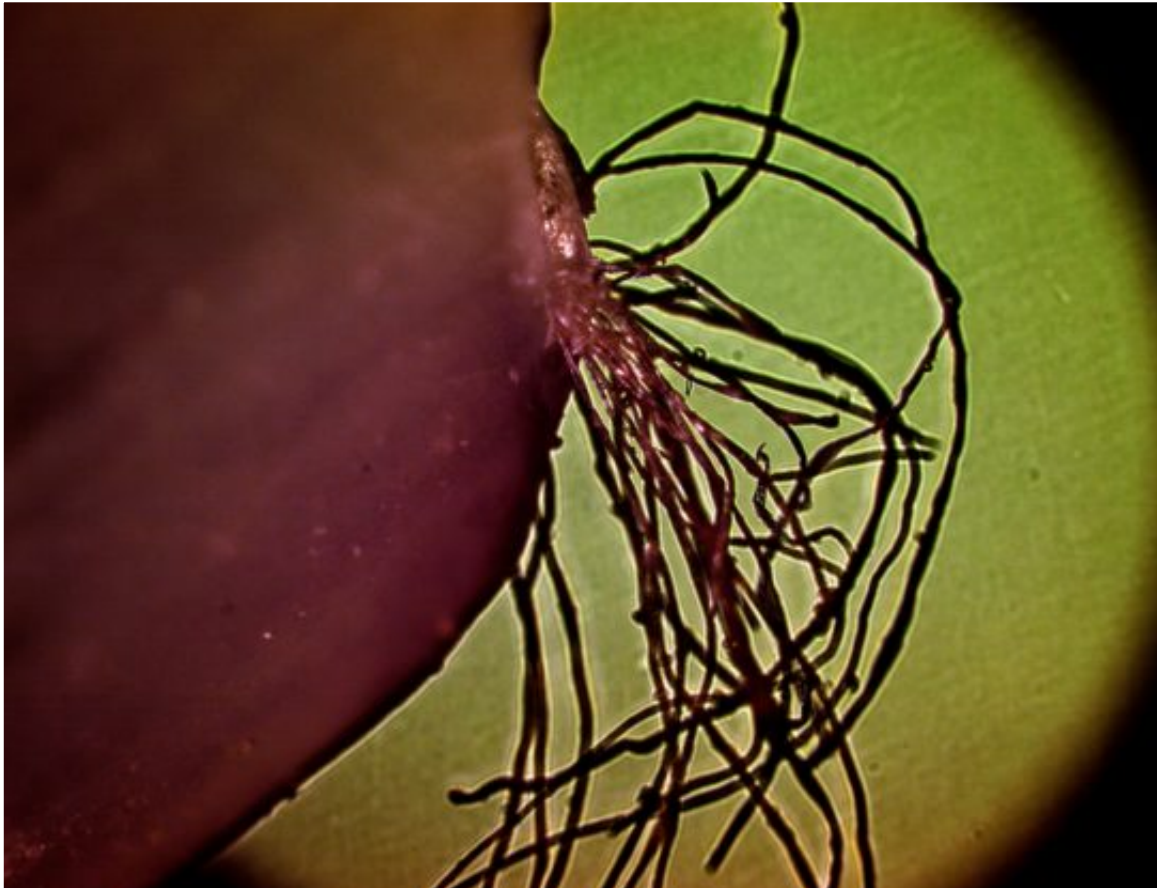The photograph below shows a toenail clipping from the individual that clearly demonstrates the growth of the unique and identifiable filament network from this same nail.



Human toenail with growth of the unique and identifiable filament network that is characteristic of the “Morgellons” condition.
Magnification approximately 15x.

The image above further establishes the uniqueness of the Morgellons condition and the unique microbiology that is causal to the condition. Any position that continues to promulgate the hypothesis or claim that the physical result above stems from conventional known microbes (e.g., *Borrelia*, *Agrobacterium*) is misdirected and false.

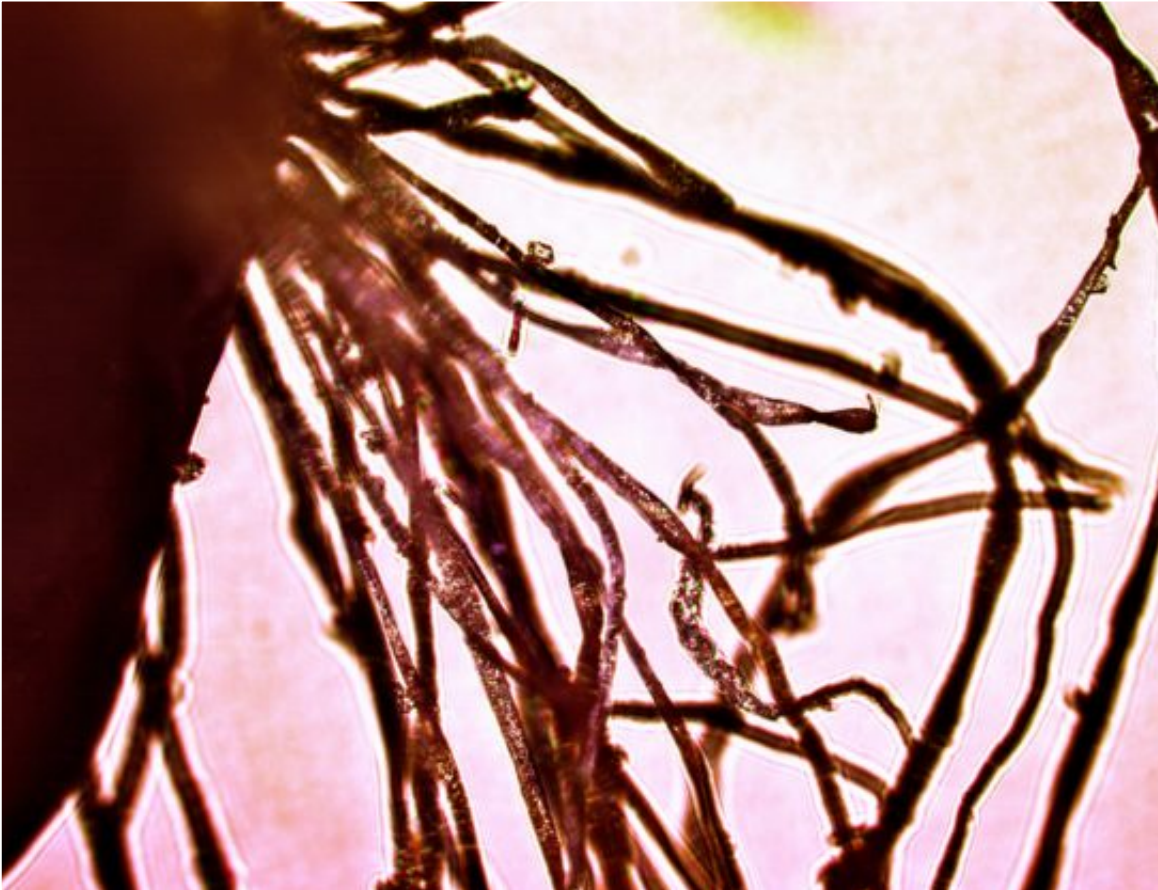Any efforts to extend this argument to create new or ambiguous “variants” of Lyme Disease, such as “chronic lyme disease”, to explain the Morgellons condition are equally misfounded. The Lyme’s condition is traced to originate from *Borrelia*, a spirochete. The microbe that causes the above condition is not a spirochete, and the microbial growth and life cycle is completely distinct from *Borrelia*. The microbe that is causal to the Morgellons condition is well researched on this site, and it is a unique and identifiable form (ref. [Cross-Domain Bacteria Isolated](#), May 2014).



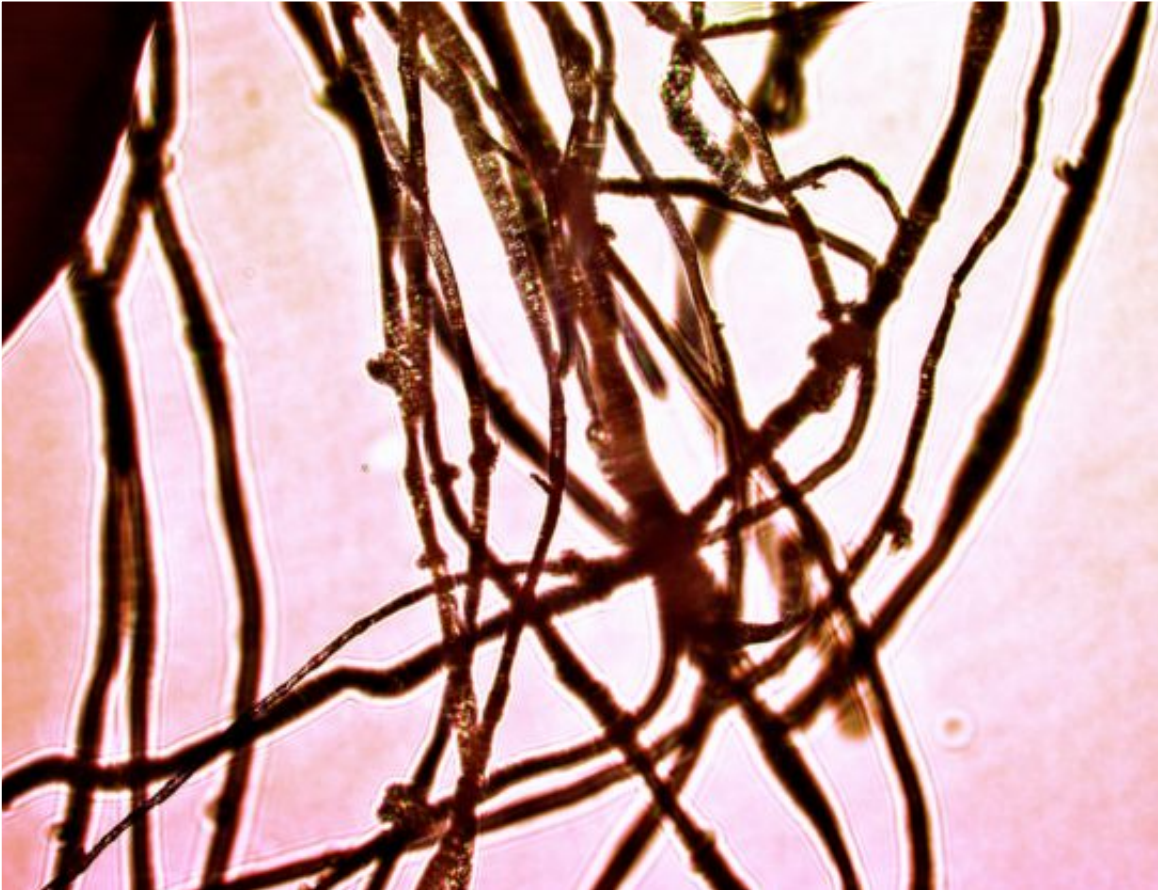
Microphotograph of growth of filament network from human toenail
Magnification approx. 300x.

Any individuals, health professionals, or organizations that continue to assert otherwise will eventually be reconciled to the facts that now exist before us. Any purported “peer-review” process that continues to reinforce mistaken information will need to redirect itself to confront this same reality. Due consideration and funding to independent researchers may serve to accelerate that required transition.

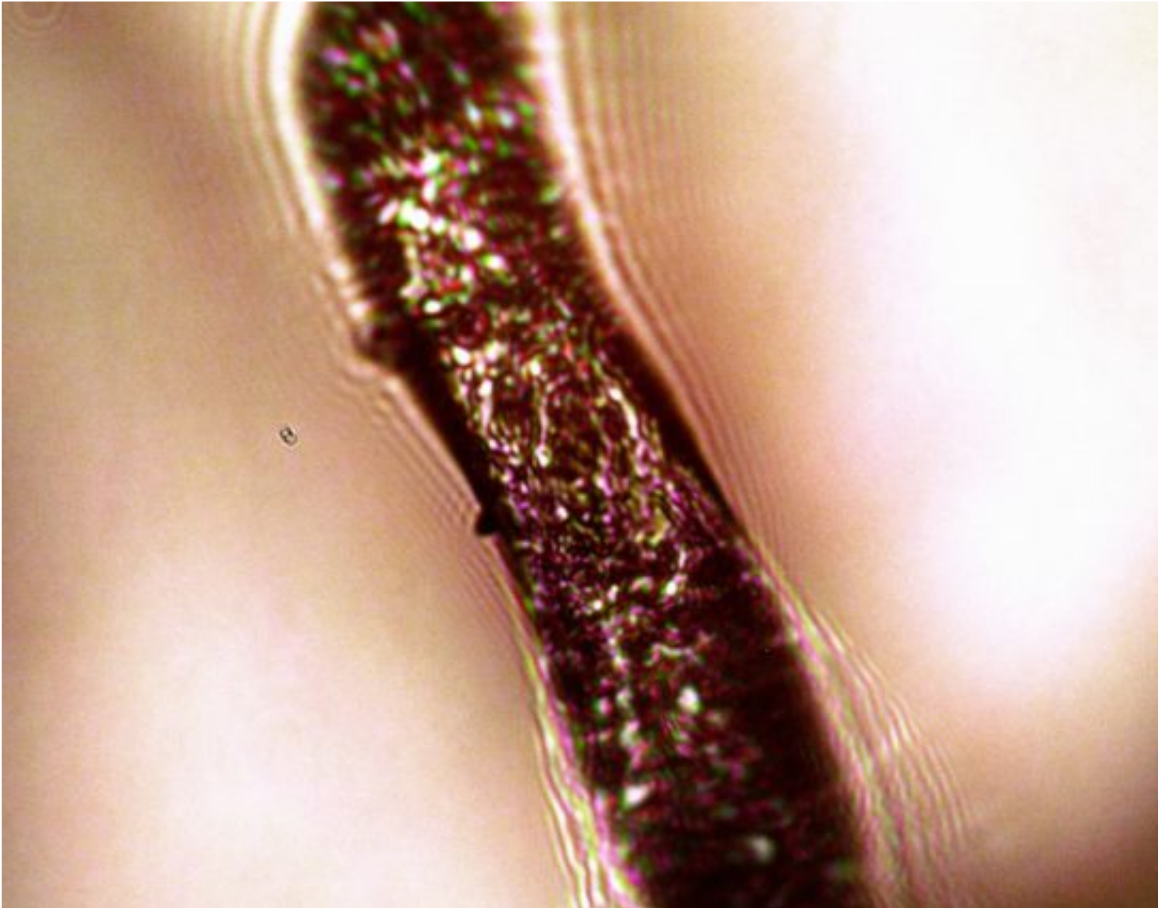
Coexisting or “associated” microbial species are not any question here; this is a common and biological state that bears no argument. Coexistence, however, is not the same as the proper and unique identification of a particular life form. DNA from the microbe causal to the Morgellons condition (i.e., CDB tentative nomenclature) has been extracted on multiple occasions and it can undoubtedly aid in resolving any questions on the matter.



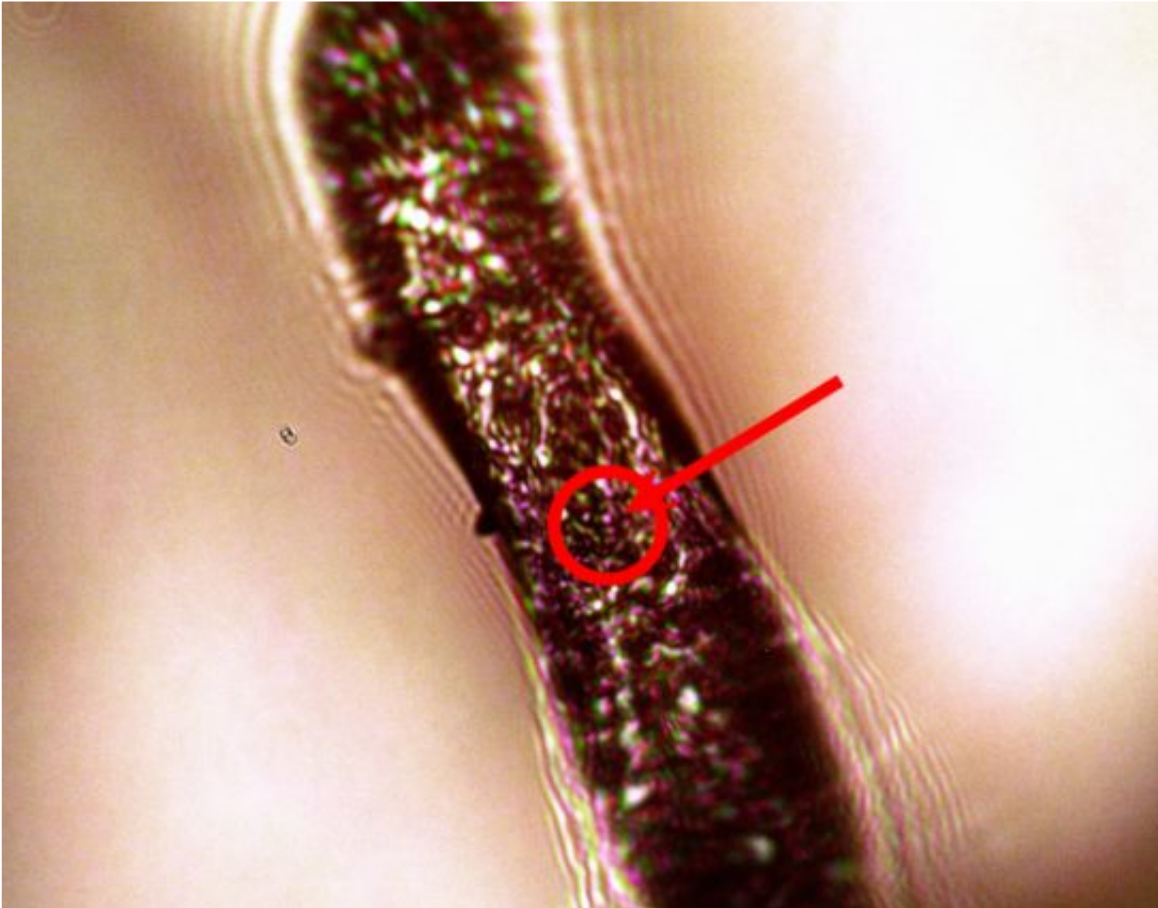
Microphotograph of growth of filament network from human toenail
Magnification approx. 800x.



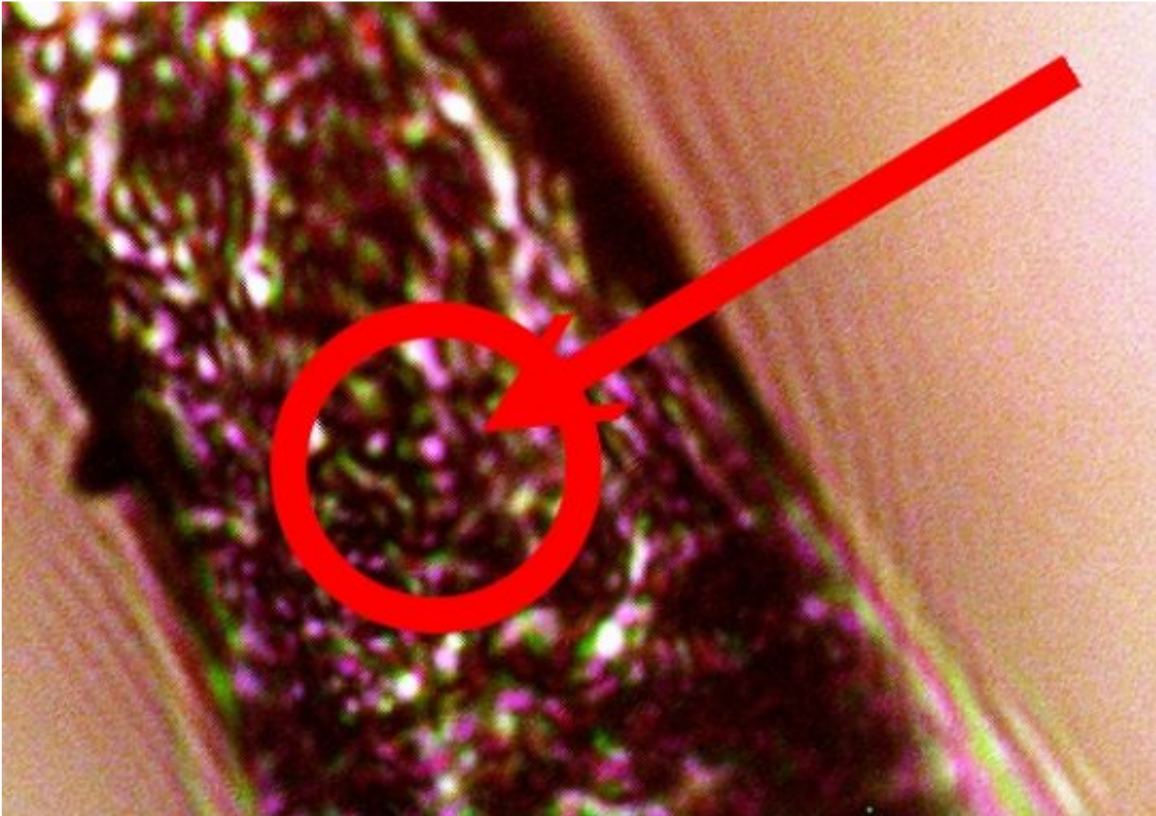
Microphotograph of growth of filament network from human toenail
Magnification approx. 800x.



Microphotograph of individual filament network from human toenail
Diameter of filament approx. 23 microns.
Magnification approx. 3200x.



Highlight of identifiable CDB within an individual filament from the network.
CDB measure at the submicron level (~0.3 – 0.4 microns estimated diameter)
Magnification approx. 3200x.



Closeup view of highlight of CDB identification within an individual filament from the toenail network growth. An example of the “cross-domain bacteria” is the small circular (cocci)form at the center of the highlighted circle; measurement of this microbe is on the order of ~0.3 to 0.4 microns diameter. Original magnification of filament is approx. 3200x.

It will be found that the unique structural, morphological, and growth characteristics of this particular filament network matches, in all respects, the prior research by Carnicom Institute that establishes the unique microbiology that is causal to the Morgellons condition.

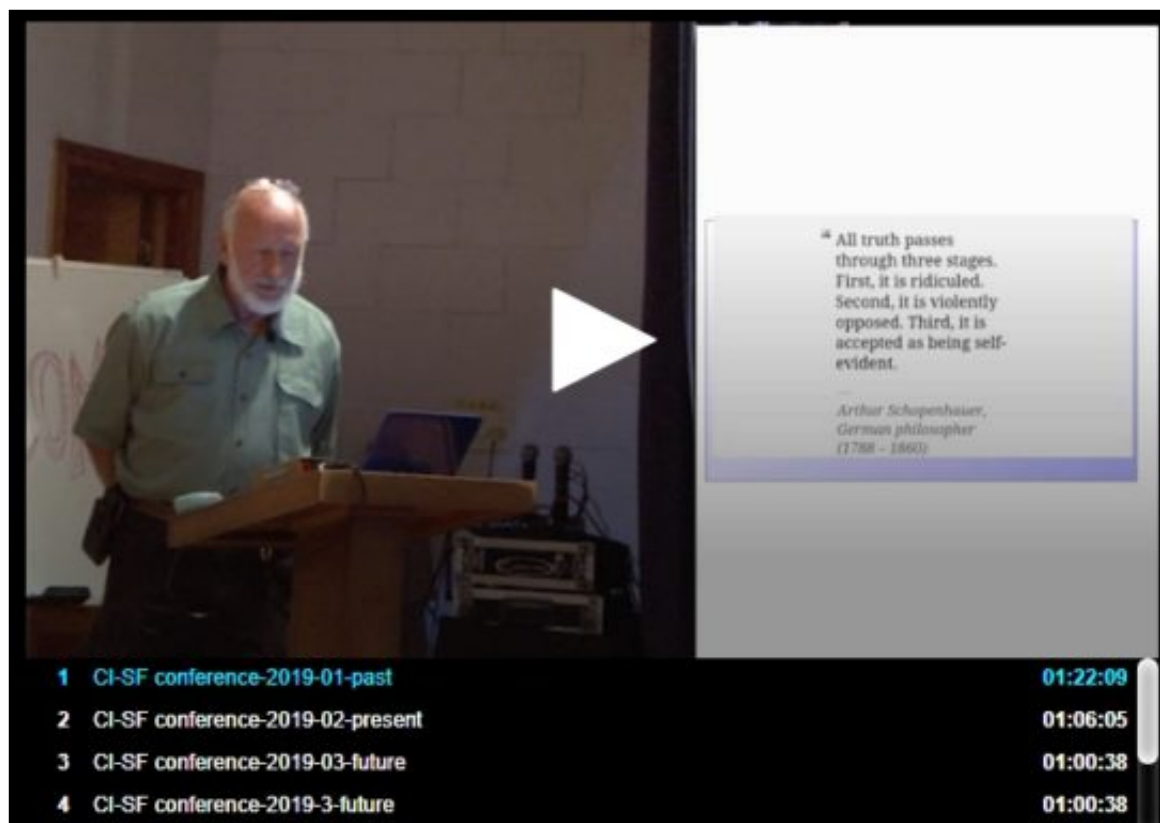
Clifford E Carnicom
Jun 13 2019

Note: Special appreciation is extended to the individual who has made this sample available for study.

Jul
Santa Fe Conference 2019
Jul 4, 2019

Santa Fe Conference
GeoEngineering & BioEngineering : The Unmistakable Link
April 27 & 28
Santa Fe, NM

The following link provides access to the recent environmental conference held in Santa Fe, New Mexico on April 27-28 of 2019. Featured speakers were Clifford E Carnicom, President of Carnicom Institute, and author Elana Freeland. This link provides access to the Carnicom Institute portion of the conference; please consider viewing the conference and distributing the conference link and information to your peers.



[Santa Fe Conference](#)
[GeoEngineering & BioEngineering : The Unmistakable Link](#)
[April 27 & 27, 2019](#)

With much gratitude, this video source is provided courtesy of reconnect-today.org

Carnicom Institute

Simple Observations, Important Conclusions

Jul 4, 2019

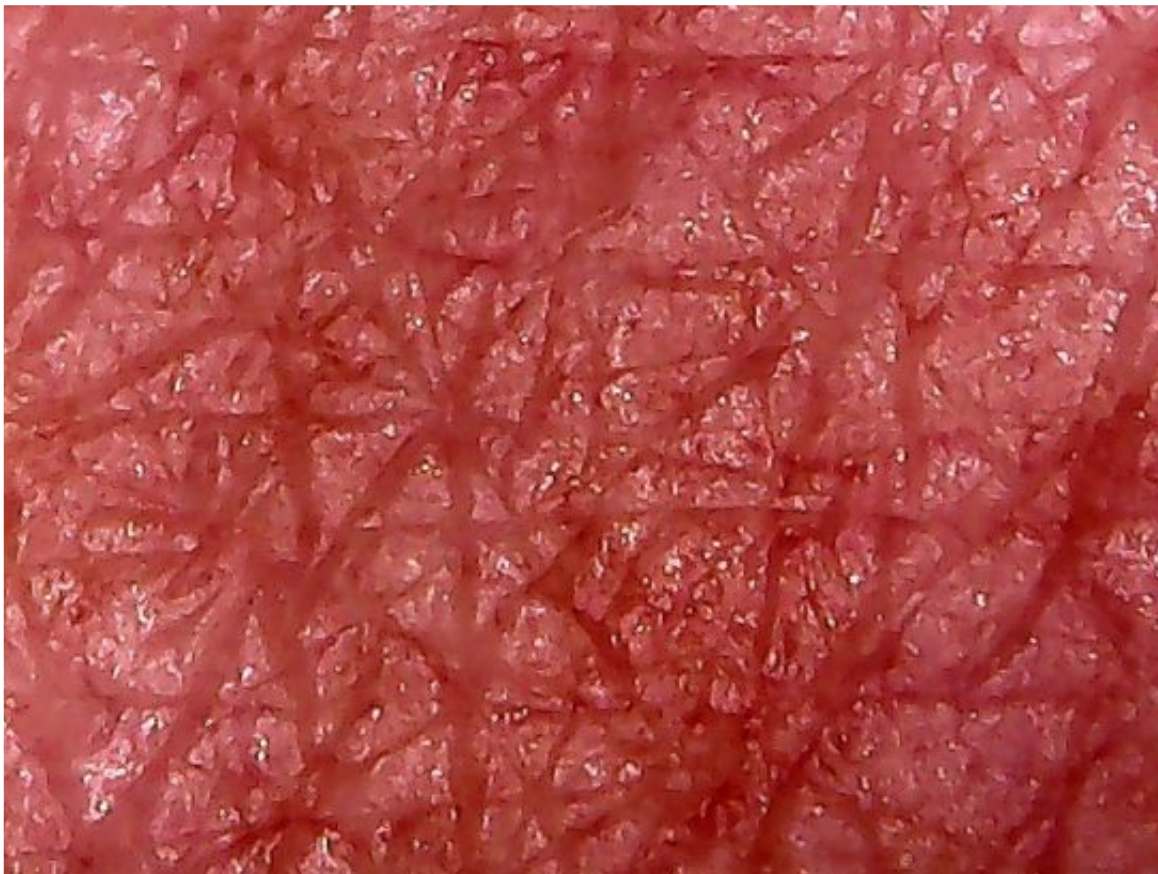
Simple Observations, Important Conclusions

by
Clifford E Carnicom
Jul 06 2019

What follows below completes a loop of an important branch of research that has taken place at Carnicom Institute throughout this last decade.

The images below will demonstrate that an exact match exists between the microbiology of the “Morgellons” condition BOTH internal and external to the body. It also, once again, confirms the studies that confirm and prove that this health condition is in no way limited to skin effects or symptoms.

The Morgellons conditions is the result of very specific and unique microbiology. The characteristics of that microbiology have been studied in great detail and sufficient information to establish and confirm this claim of uniqueness exists on this site. The presentation in the paper [“Cross-Domain Bacteria Isolation”](#) (May, 2014) solidifies that claim in the evolution of research. The provisional term, “cross-domain bacteria”, is henceforth referred to as CDB in this and other papers.

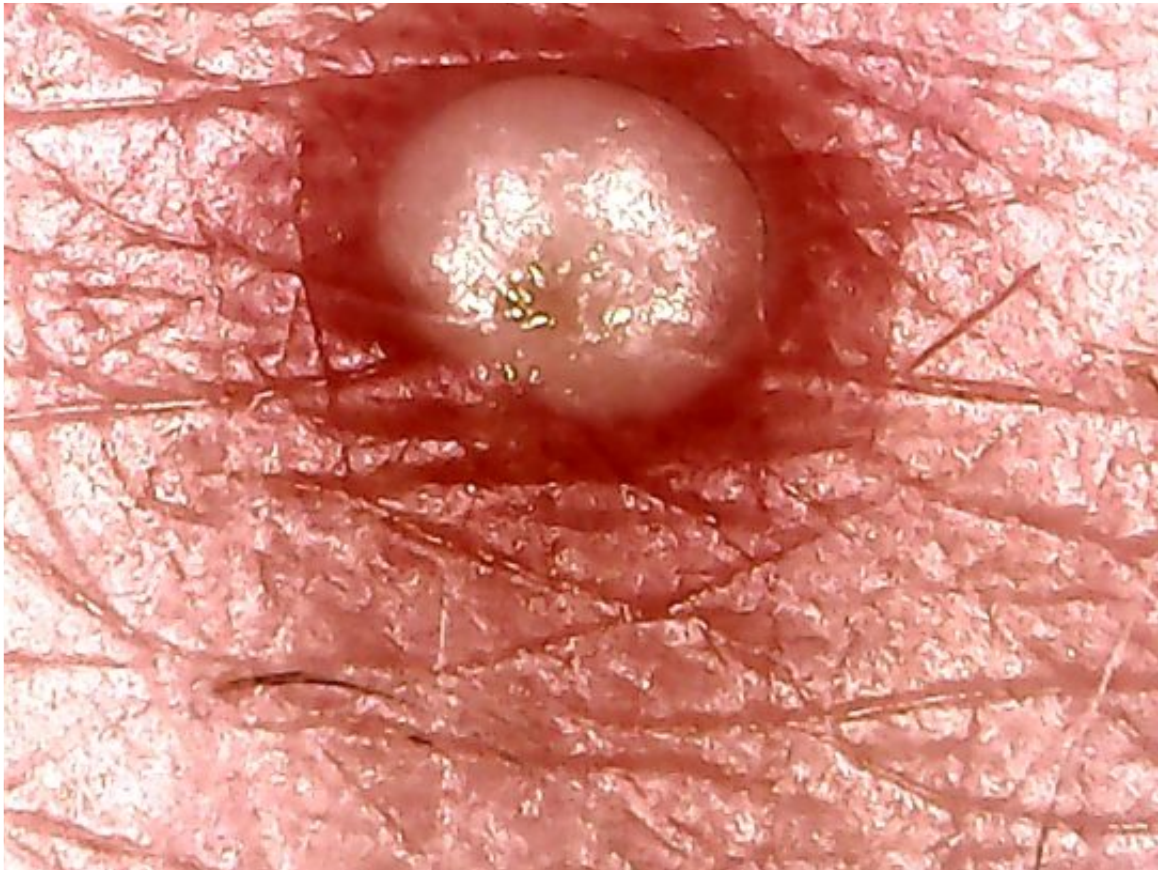


Control

Photograph – Normal Skin
No skin blemishes visible or apparent.
Magnification approximately 15x.

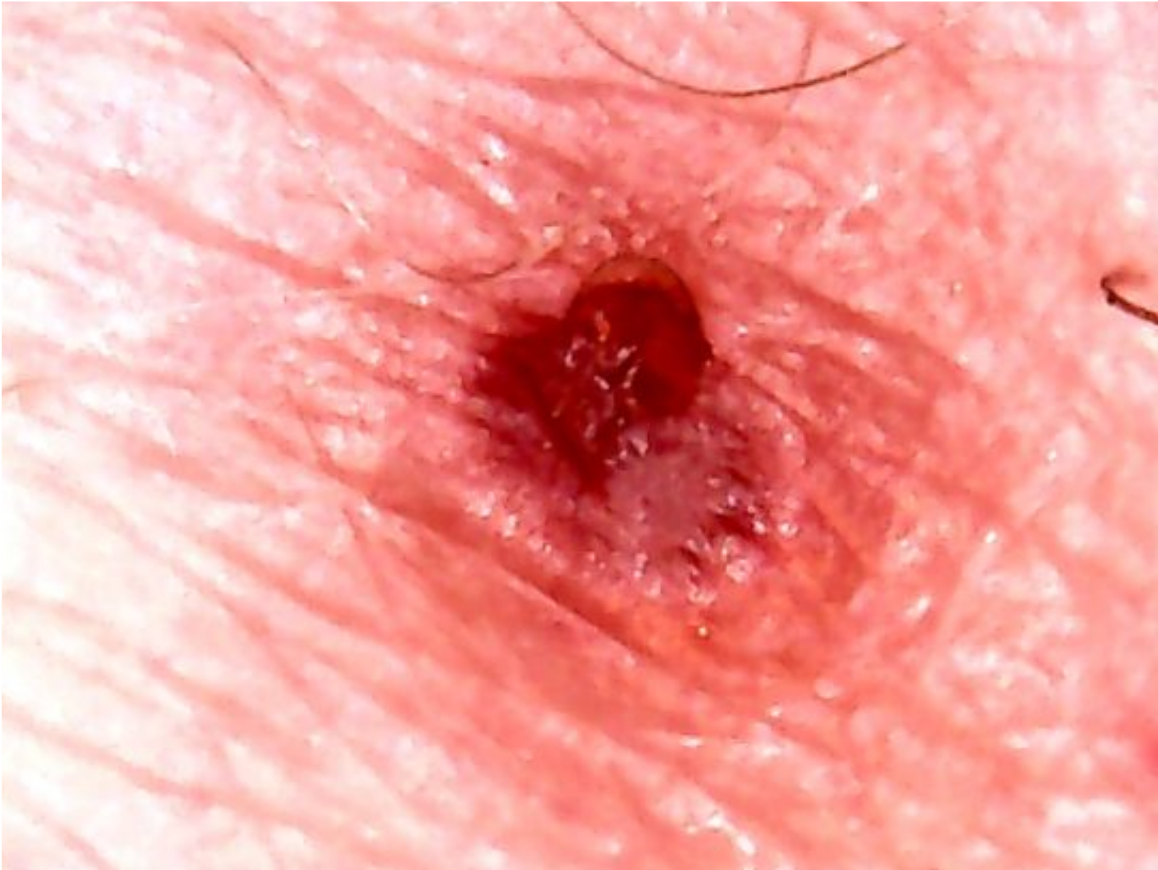Further uniqueness of this microbiology has been established in the recent published paper, "[The Evidence is Evident](#)" (Jun 2109). All comments within that research paper apply equally toward the information that is presented here, and it would be apropos to be equally familiar with that previous work.

The following two images depict a type of skin anomaly that presents itself within the "Morgellons" condition. These can exist at numerous locations on the body, and they are strongly irritating. In the case shown here, the disturbance is small and not readily visible to the naked eye.

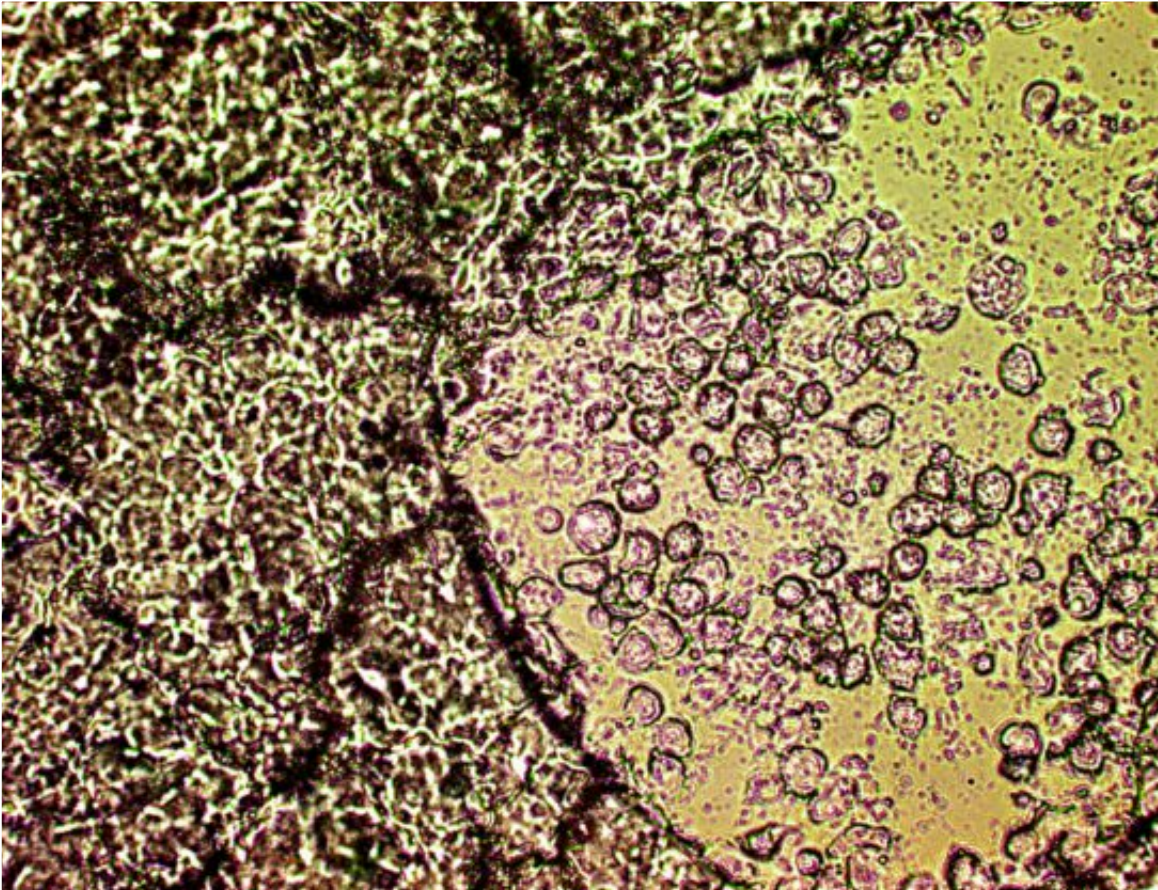


Microphotograph of a skin blemish from an individual that displays symptoms characteristic of the Morgellons condition
Magnification approx. 15x.

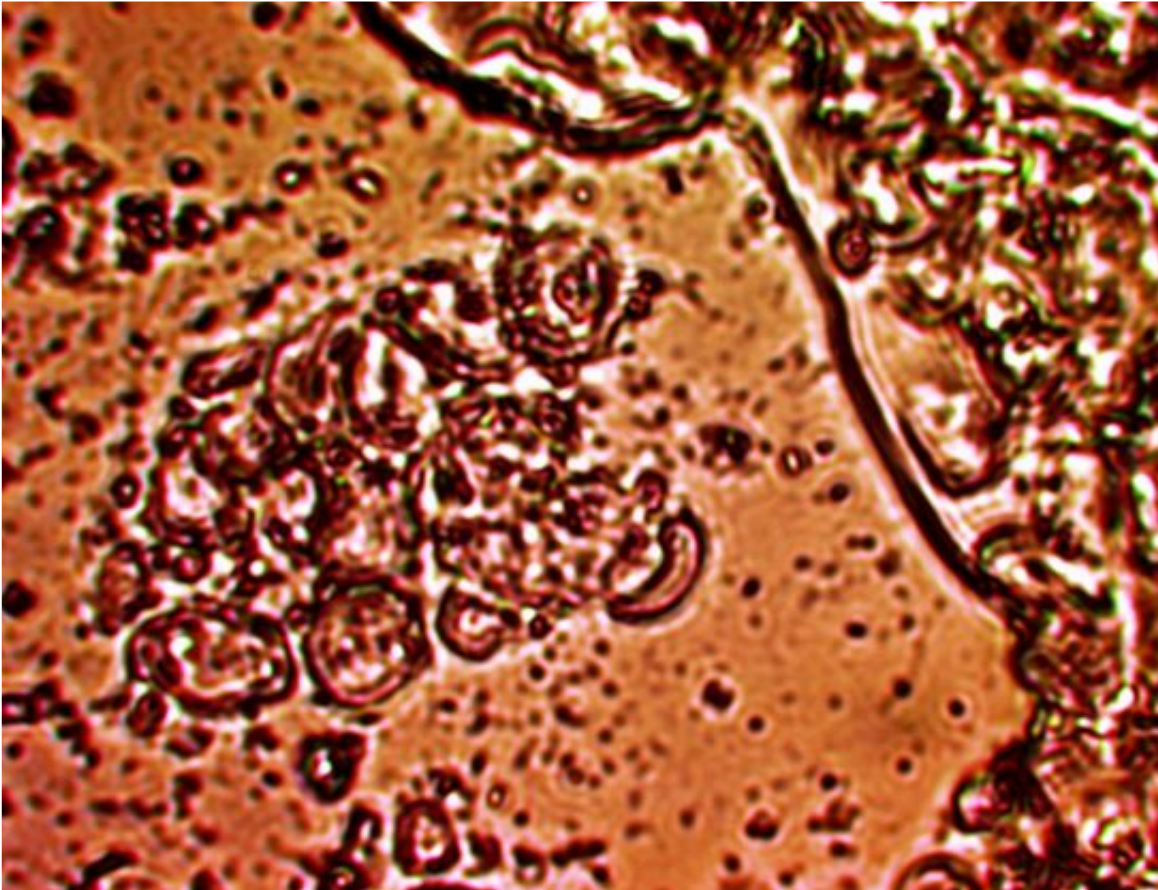
The skin disturbance shown above was opened slightly to retrieve a small exudate sample for observation under the microscope.



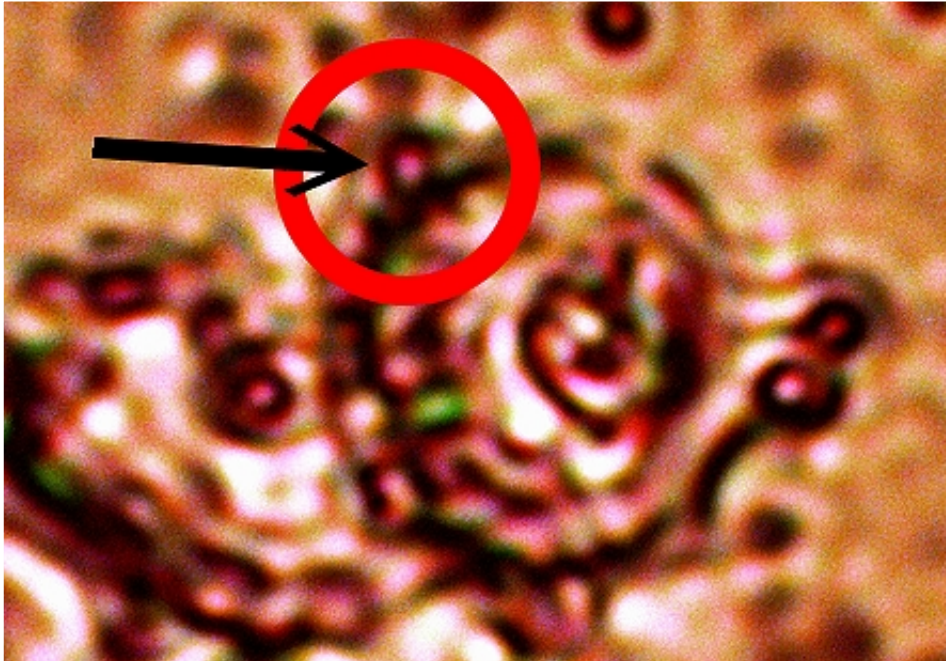
Microphotograph of blemish that has been opened to remove exudate .
This image is from an individual that exhibits external symptoms
of skin conditions that are characteristic of the Morgellons condition.
Magnification approx. 15x.



A microscopic view of the skin exudate at moderate magnification. No special detail is evident here, however, signs of a filamentous composition can be observed in the left side of the photograph. In addition, cellular structures with signs of disruption can be seen in the right half of the photographs. No significant conclusions regarding detailed structure or variation can be determined at this level. Magnification approx. 3200x.



A microscopic view of the exudate at high magnification. Due to the small size of the CDB (approx 0.3 micron), this higher level view is required to extract the detail necessary to assess the internal structure of the exudate. The assessment is that numerous damaged or broken erythrocytes (red blood cells) from the exudate are infused with large numbers of the CDB microbe. The filament structures that accompany the CDB microbial growth are also more readily visible. Magnification approx. 8000x.



Closeup view of individual CDB within disrupted erythrocyte representative of skin exudate. Size of CDB is approx. 0.3 micron. Original magnification approx. 8000x.

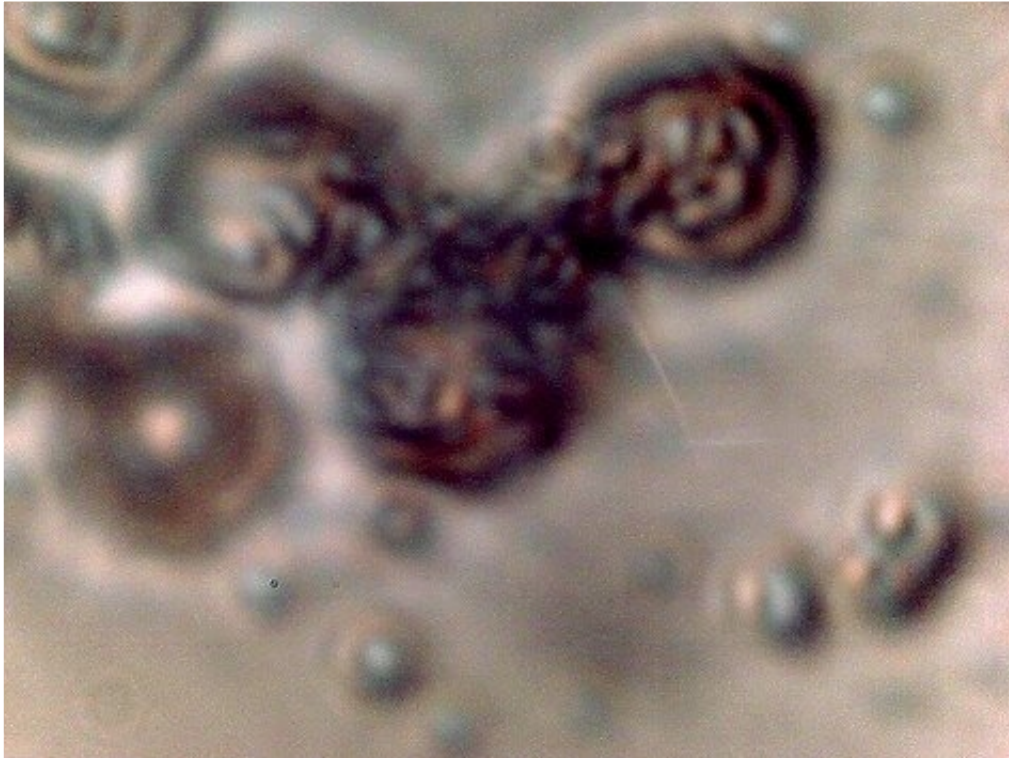*The microscopic observations above bring to immediate recall an earlier analysis made approximately **one decade ago** in a research paper titled, [“A Mechanism of Blood Damage”](#) (Dec, 2009)*

The introductory statement made at the time of that paper was as follows (**Dec 14, 2009**):

“An organism and a method that damages the condition of the blood has now been identified and it has been directly observed. The blood variations reported here are in direct association with the existence of and the severity of the so-called “Morgellons” condition.”

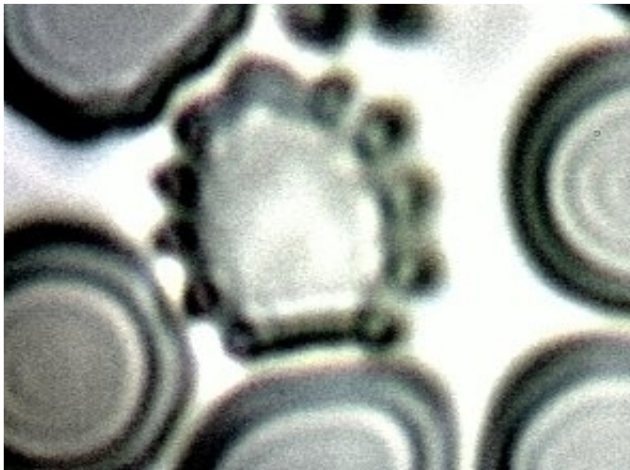We are therefore at a point, approximately a decade later, to assertively claim that what is exuded through the skin of those affected by the Morgellons condition is an exact microbiological match to that which is known to exist within the blood and body fluids of those affected by this same condition. This microbiology is now well established, and is no longer subject to ambiguous debate. Readers are once again referred to the recent paper “The Evidence is Evident” for additional substantiation of these facts.

We shall now recall a couple of the images of affected blood that were presented close to one decade ago within the reference paper cited above, “A Mechanism of Blood Damage”.

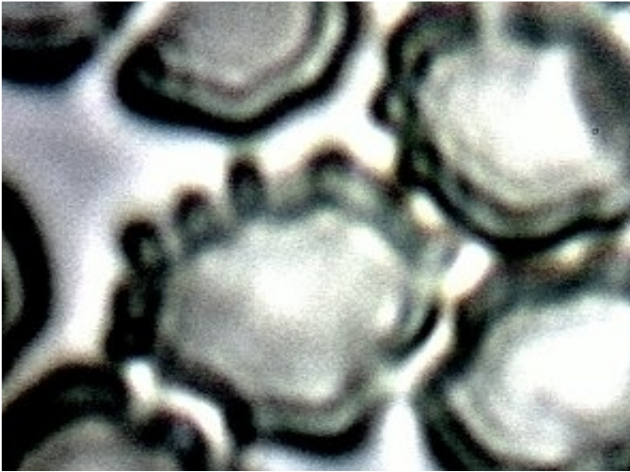


Magnification of highly

degraded erythrocytes (red blood cells) heavily infused with the CDB microbe. The blood shown here is venous and comes from internal to the body. This image was reported in Dec. of 2009. The structural details of microbial damage in this case match exactly the form, style and method of erythrocytic damage shown in this current report. Magnification approx. 7000x.



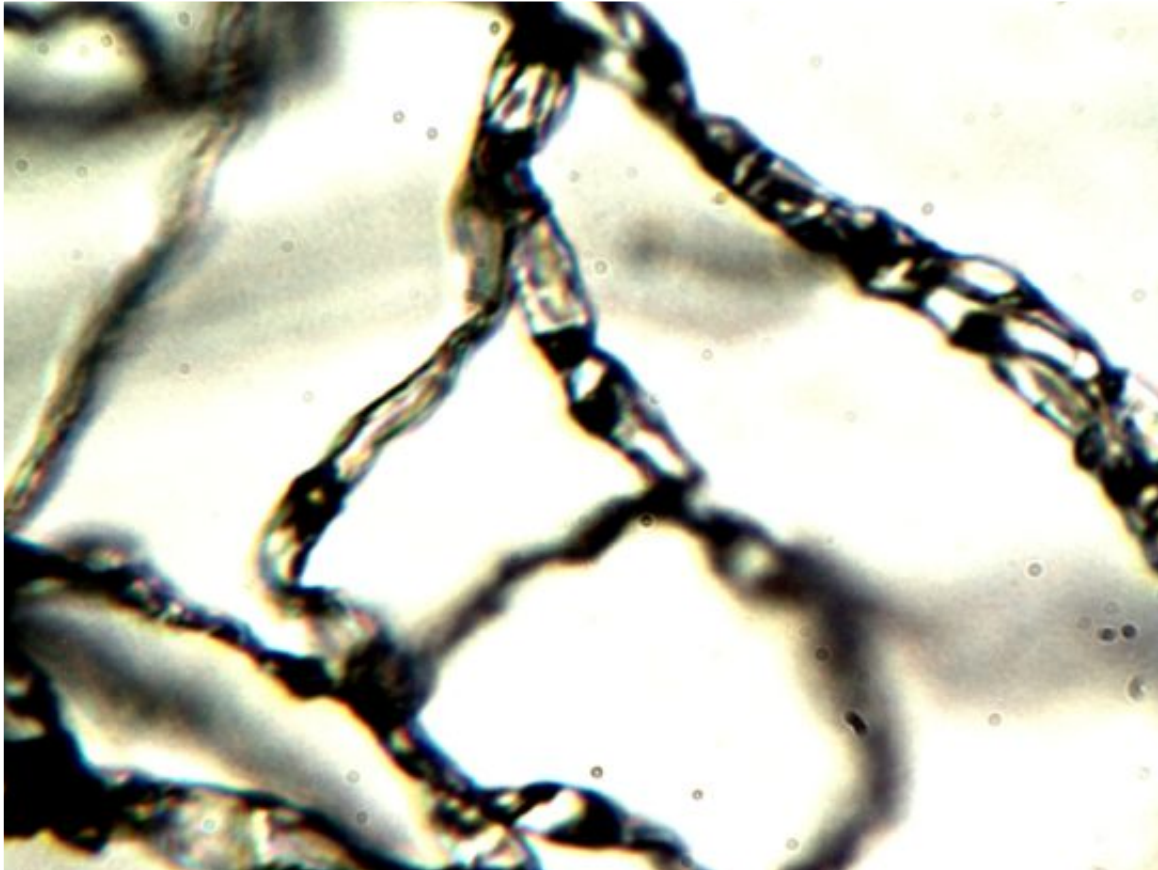
Erythrocytes (red blood cells) in the process of degradation by the CDB microbe. The blood shown here is capillary and comes from internal to the body. This image shows an earlier stage in the evolution of damage to the cells, as reported in the "A Mechanism of Damage" paper. This image was reported in Dec. of 2009. Magnification approx. 10,000x.



Additional image of earlier stages of degradation of erythrocyte by the CDB, as reported in 2009. Magnification approx. 10,000x.



To further demonstrate the co-existence of filamentous growth and its origin from the CDB, these images show filaments that are also known to be characteristic of the Morgellons condition. The filament structures here were exuded from the same individual that provided the skin exudate samples of this current report. These filaments developed in hair-covered portions of the body, and they were collected approximately six months prior to this report. Moderate magnification (~ 800 – 1200x)



An additional microphotograph of the filamentous growth from the skin of the affected individual.
Higher magnification (~ 2000 – 500x)

The definitive findings of the microbiological origin and nature of the Morgellons condition (i.e., CDB) are ultimately to be recognized and acknowledged by the scientific and health communities. The research is established to the point where avoidance and/or obfuscation is no longer permissible or acceptable. Those that are able to act independently often are more receptive, flexible, and progressive with such change. Governments are likely to be the slowest to follow suit. If the motive to improve the state of our well-being exists, significant financial infusions will be required. The pace of that acknowledgement and acceptance is a process that we are all, inevitably, involved with.

Clifford E Carnicom
Jul 06, 2019

Additional note: Near infrared (NIR) scans of affected skin areas and of control normal skin have been collected to further establish the microbial signature of the Morgellons condition.

Complex Observations, Unknown Consequences

Jul 7, 2019

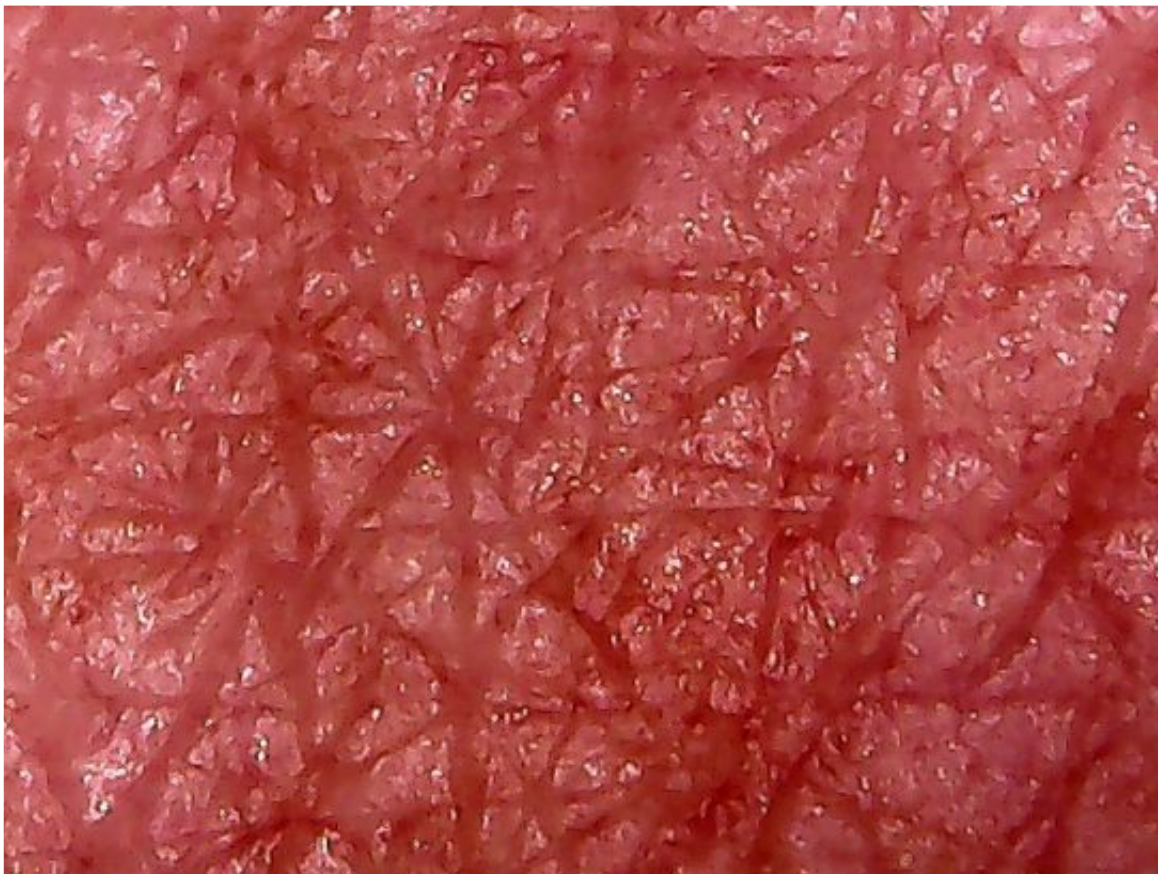
Complex Observations, Unknown Consequences

by
Clifford E Carnicom
Jul 07 2019

This paper introduces some of the more enigmatic developments that have come within the scope of research at Carnicom Institute, with special emphasis upon certain anomalies observed during the last year. There is now an element of geometry and 'order' within the examination of the microbiology that is known to be causal to the Morgellons health condition that is puzzling, but nevertheless appropriate to disclose.

A previous reference paper, titled, "[Simple Observations, Important Conclusions](#)" (Jul 2019) will be called upon to provide perspective as to how a single observation can sometimes provide alternative interpretations of its nature.

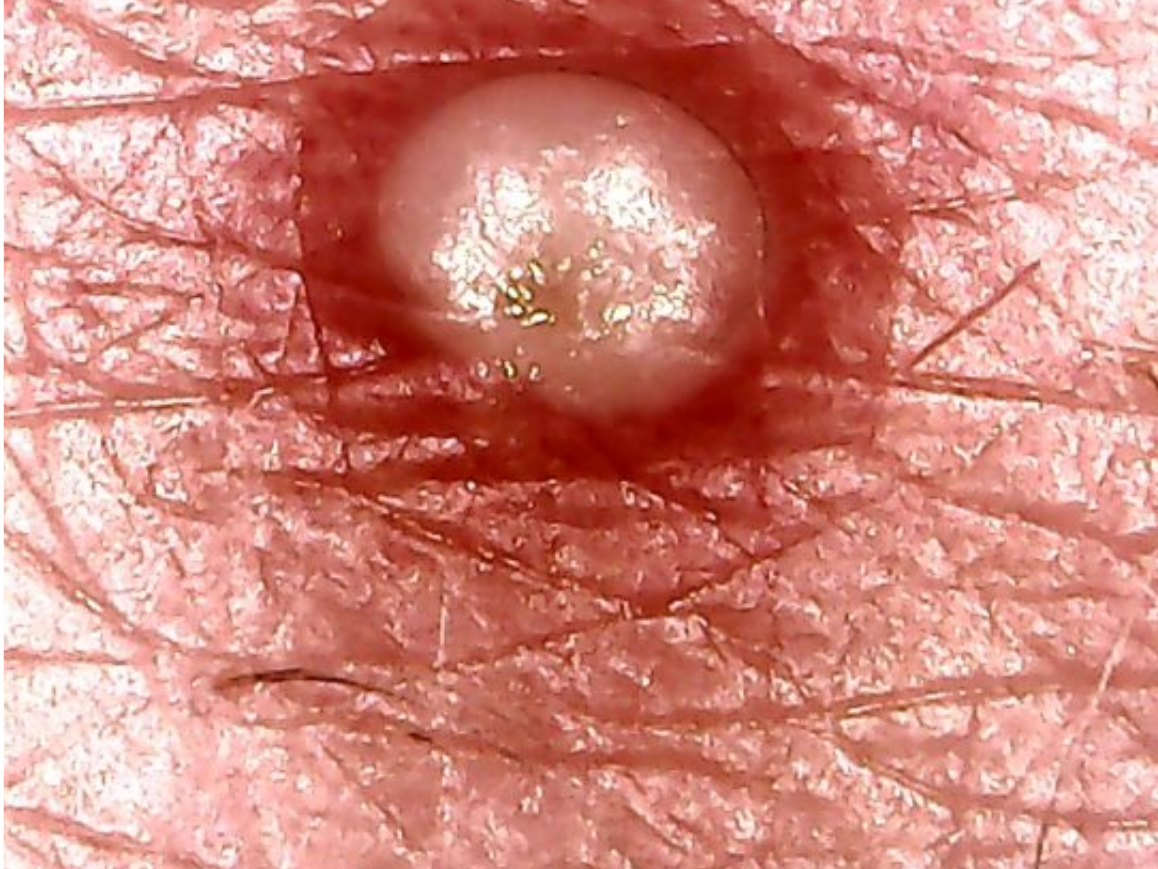
We will start the discussion with a comfortable reference point, and that is an image of normal skin under the microscope at low power. Such a representative image is shown immediately below:



Control Photograph – Normal Skin
No skin blemishes visible or apparent.
Magnification approximately 15x.

At this point there are no surprises, other than many readers may, understandably and with good cause, marvel at how fascinating and interesting even *normal* skin appears when magnified.

Our next step is to return to an image presented in the earlier paper reference above:

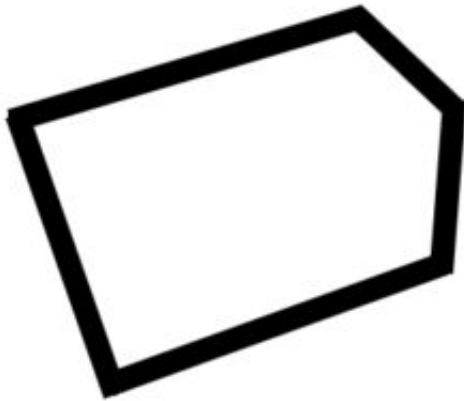


Microphotograph of a skin blemish from an individual that displays symptoms characteristic of the Morgellons condition
Magnification approx. 15x.

This observation was discussed at length in that earlier paper, and the points within that paper have already been made. The focus of that discussion was on what now must be regarded as the more obvious interpretation from the image above, that being the rather blatant disruption to the skin surface . Although simpler in fact to understand, nevertheless, such a simple observation leads to some rather profound and important conclusions. These have been brought forth in the “Simple Observations” paper, and I encourage you to become familiar with that work.

There is, however, another development within this image that deserves our attention.

There is an anomaly that exists within this photograph, and this is the geometric outline that surrounds the skin sac inflammation. I am aware of a set of peculiar observations , some time past, at the micron level that demonstrated a similar unusual geometry, i.e, of the form:



Anomalous geometric shape accompanying various

observations

in conjunction with study of the Morgellons condition.

One important curiosity here is that of scale; the skin disturbance above is on the order of a 1000 times larger than that of the microbial observation that I am aware of.

It is also known that hexagonal crystal forms have been observed in association with the Morgellons condition; I am aware of two such cases directly.

It is now appropriate to recall some of these observations that have taken place across related sample types. The synthesis of this information may help to provide a direction and focus for any questions of crystallography, geometry, or “order” that may arise in the future with respect to the most extraordinary and unusual health condition know as “Morgellons”.

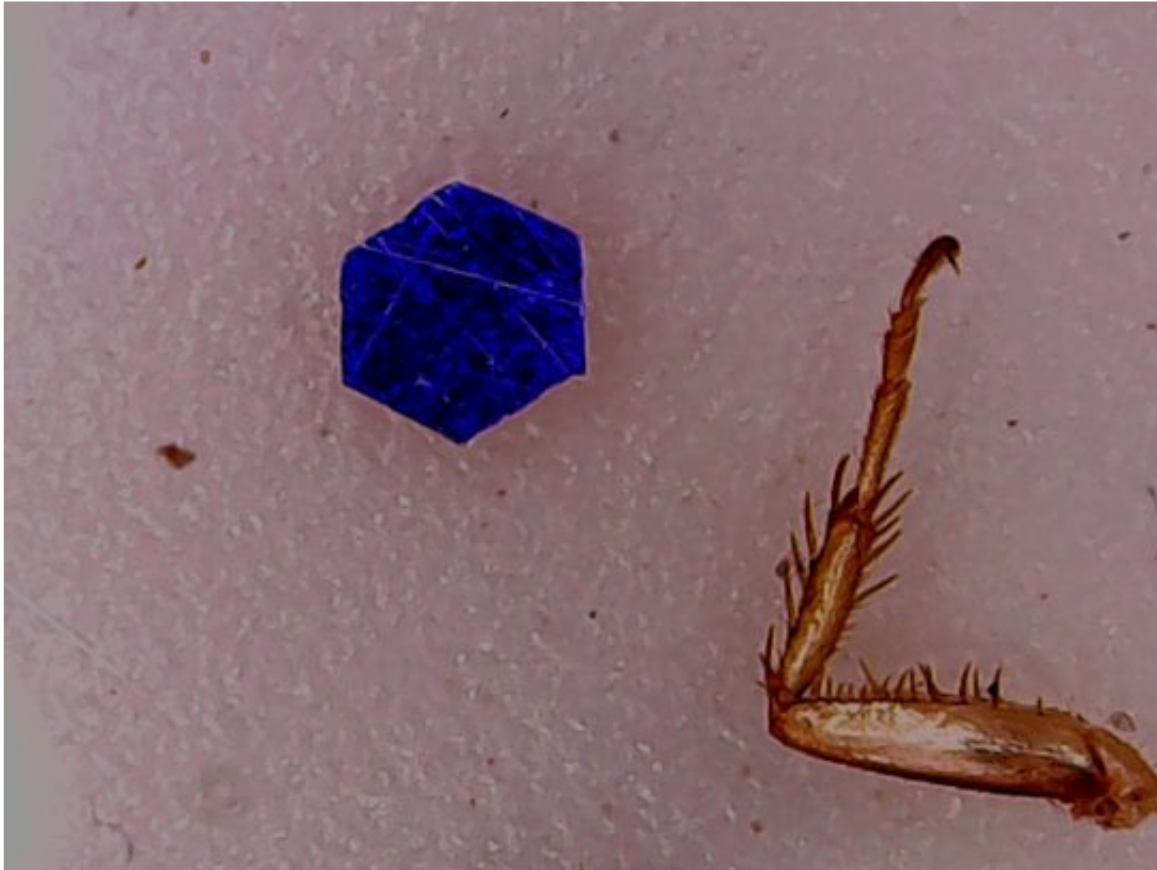
The evolution of our discussion now requires a brief interlude; I can only assure you that the apparent diversion is ultimately only apparent. The connections between observations and sample times does eventually become increasingly complex.

This interlude involves the examination of some insect specimens that were received. Insect associations with the Morgellons issue are pervasive, but at this point the Institute does not have the evidence to overwhelmingly forward that case. Nevertheless, an insect lair and collection has been received and examined under low power under the microscope. The most definitive conclusion that can be made from this work is that insects seem to undoubtedly act as an effective transport mechanism for the filament growth that is characteristic of the CDB microbe. This should not actually act as any surprise to those that understand the now omnipresent distribution of the CDB microbe; HEPA air filters can easily make that case to those that wish to comprehend the biological changes now in place.



Insect samples under observation (note characteristic filaments present)

Now we advance to the next stage of analysis, and a photograph of that result is shown below. In addition to the CDB microbial filaments existing within the various insects observed (i.e., “transport” conclusion at a minimum), a brightly colored hexagonal crystal was observed amidst the insect collection. Even without any additional information available, it represents a striking and unusual observation.



Observation

of brightly colored hexagonal crystalline structure found within a received insect collection/lair. Magnification approx. 15x.

This exact crystal form, structure and size is now the second of two crystal that have been witnessed by this researcher in association with the Morgellons research. Anecdotal mentions of this crystalline structure are reasonably frequent and the topic is one worthy of serious research. Adequate availability of sample material has been a major limitation to furthering the research at this site. The colors of the hexagonal crystals appear to vary; this one is especially bold blue in color. Such bold colors are identical and common within the CDB microbial filament growth.

This paper has its title for a reason; I hope that the reader will be patient to pursue its course to the end. We are getting closer.

The reasons for presenting the hexagonal crystal form in this discussion are as follows:

1. The appearance of geometric constructs, “natural” or otherwise as will ultimately be determined, is now a regular feature of the so-called “Morgellons” landscape, so to speak.
2. Direct evidence, in the form of the observations and analyses within this paper, are now available to show such geometric development occurring within or surrounding human skin and known CDB microbial filament growth. Circumstance might be used to attempt to separate the hexagonal crystal from the insect CDB transport or growth, but the evidence is no longer favoring that course.
3. The anecdotal reports, as well as a large body of public research images, now strongly confirm the developments of the hexagonal crystals within those affected by the Morgellons condition. Sufficiently detailed accounts and information beyond the anecdotal level is required for this Institute to advance that

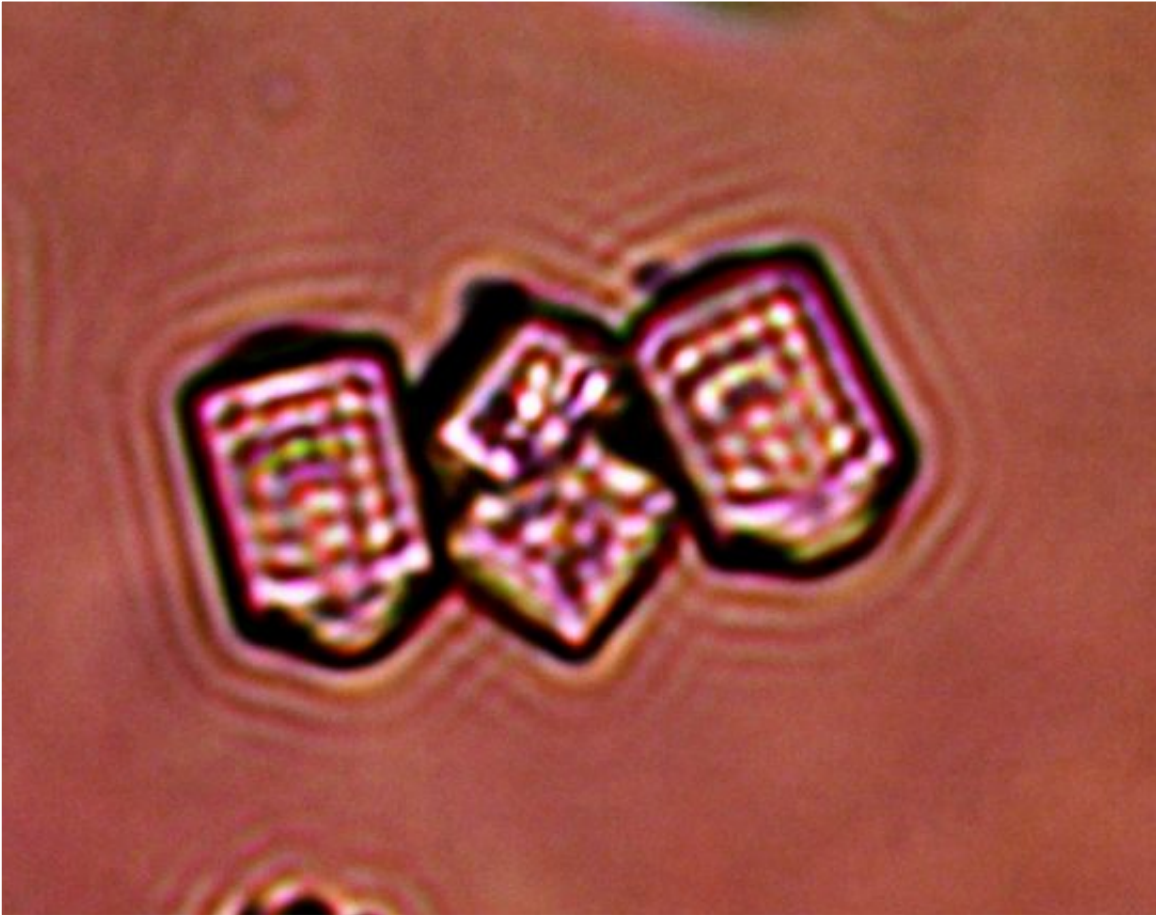
investigation further.

4. An even closer examination of the affected skin photograph above might introduce the issue of hexagonal crystal formation itself; the data at this point is simply not available to make that assessment properly. Hopefully in shorter order it will become so.

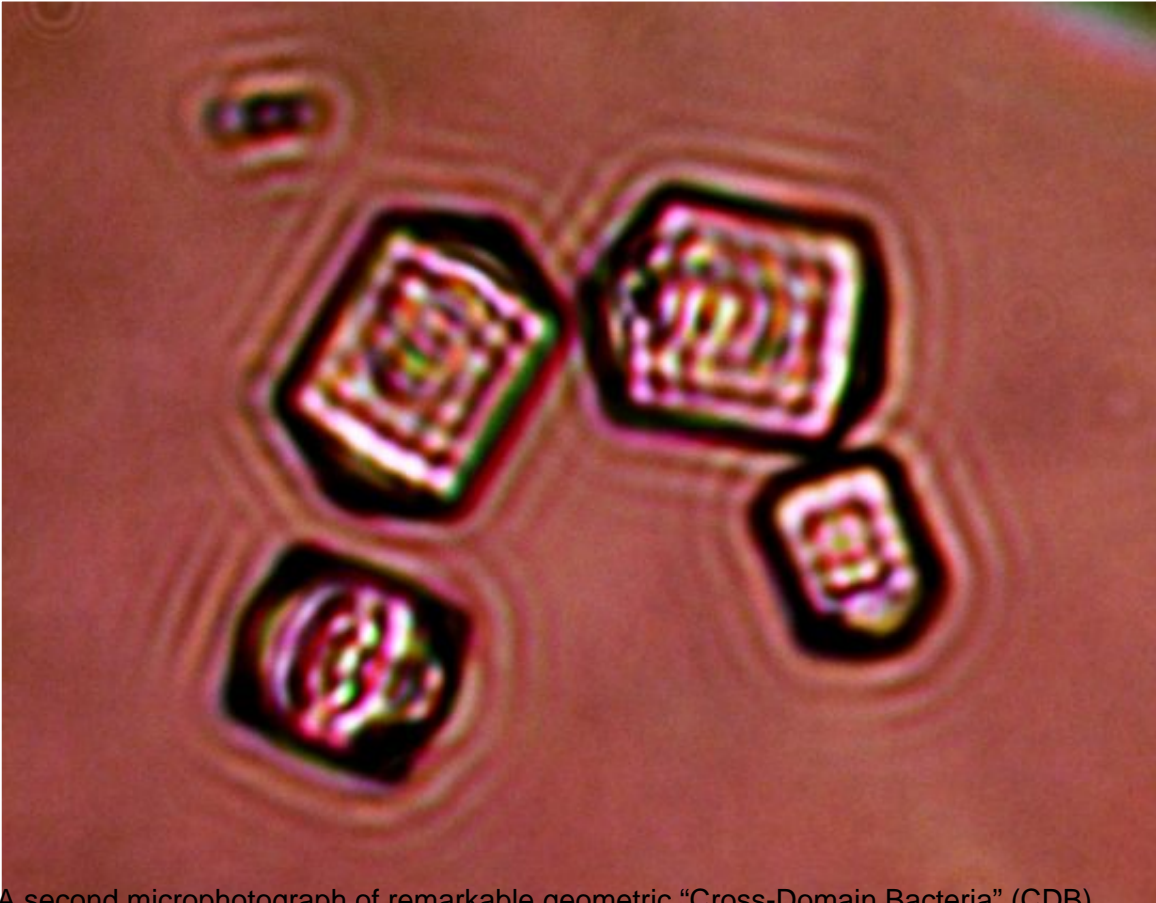And now, for those that have tempered their curiosity to this point with patience, there is a final and rather profound introduction of “geometry” before us. The images that are shown below should introduce some level of curiosity and amazement to even the most cynical or skeptical researchers in the audience. I think that it is fair that some important questions here deserve to be answered. The Institute will continue to do its part, although it is only fair to understand that the base of investigation here is much broader than this limited organization is privy to.

The circumstances of observation here are as follows:

1. The case involves observation of a urine sample that was in cold storage for approximately 6 months.
2. The observation should be regarded as a rarity at this point, and occurring more by circumstance than by plan or design.
3. Repetition of the event is not immediately available, due to the length of incubation that may be required to produce it.
4. The observation most certainly involves the CDB microbial growth, as other telltale signals of that growth have also been recorded separately for the record.
5. Significant, highly significant “geometric” development and formation involving the CDB microbe is most definitely on display here. Such observations at this level of uniqueness have never before been witnessed or recorded by this researcher in the two decades of research that precedes it.
6. The images shown below are quite small in relative terms, and would not even be visible with conventional microscopy. The approximate length of each unit is on the order of 2-3 microns, and each individual CDB microbe within is approximately 0.3 microns in diameter.
7. What is clearly shown is the repeated ‘ordering’, or arrangement of the CDB microbe in a geometric sense, akin to that of crystalline type formation.



Microphotograph of remarkable geometric “Cross-Domain Bacteria” (CDB) arrangement and development within an incubated urine sample. This represents the revelation of “ordered” structure of the CDB (“Cross-Domain Bacteria”) microbe that is known to be causal to the Morgellons condition. Each small sphere visible is a single CDB microbe that is approx. 0.3 microns in diameter. The period of incubation for the urine sample is approx. 6 months. Approx. magnification is 8000x.



A second microphotograph of remarkable geometric “Cross-Domain Bacteria” (CDB) arrangement and development within an incubated urine sample. Approx. magnification is 8000x.

And this, then, is where the enigma leaves us for the present moment. There are indeed unknown consequences to what this research now presents to us. There are obviously some important questions to ask here. One of these most certainly involves investigating the ‘driving force’, or cause of geometry now being introduced into the extensive microbial study that has brought us to this point. It is certainly warranted to open the discussion as to whether or not a biological ‘circuit’ or ‘network’ is established here. The distinction between nature and artificial design has certainly been presented to us, whether we welcome the prospect or not.

Conclusions should not be drawn before they are warranted. I encourage us all to make the efforts necessary so that the proper conclusions can be established as rapidly as possible.

With best regards,

Clifford E Carnicom
Jul 07 2019

Nov**The Transformation of a Species?**

Nov 28, 2019

The Transformation of a Species?

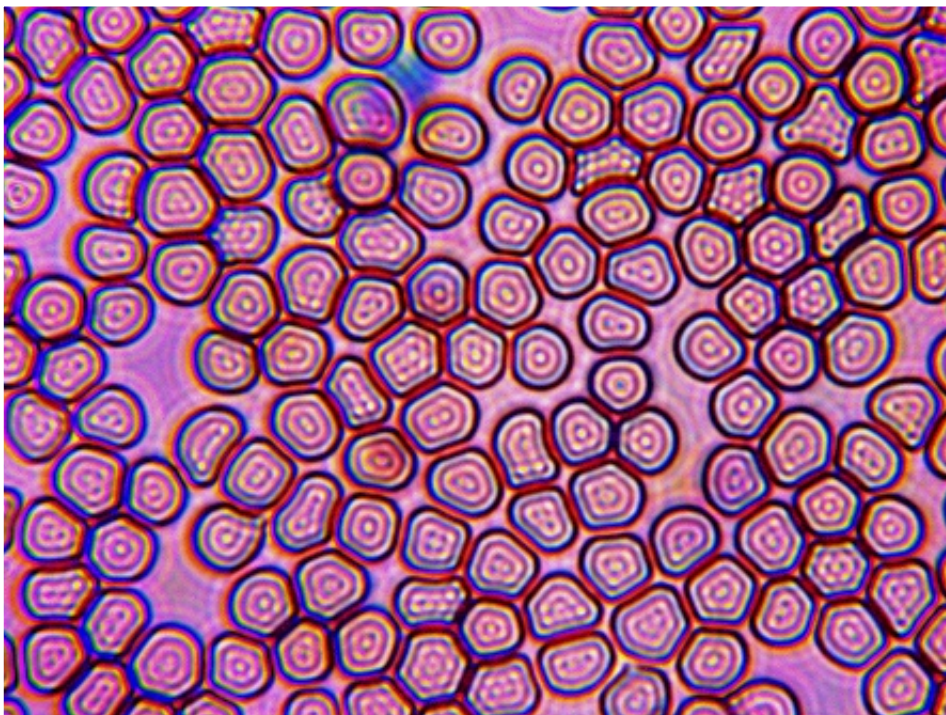
by

Clifford E Carnicom

Nov 28 2019

Note: Carnicom Institute is not offering any medical advice or diagnosis with the presentation of this information. CI is acting solely as an independent research entity that is providing the results of extended observation and analysis of unusual biological conditions that are evident. Each individual must work with their own health professional to establish any appropriate course of action and any health related comments in this paper are solely for informational purposes.

An important and consequential set of observations has taken place over the course of this last year. The subject of discussion is that of human blood. The observations raise the spectre and the very real possibility of the literal transformation of a species. In this case, the species is the human being.



Anomalous Human Blood

Under Disclosure

Carnicom Institute – October 2019

The data set upon which to draw definitive conclusions remains limited. Nevertheless, each individual that has been observed does show a common thread of anomalous disturbance within the blood, and the only variable to date is the degree of change.

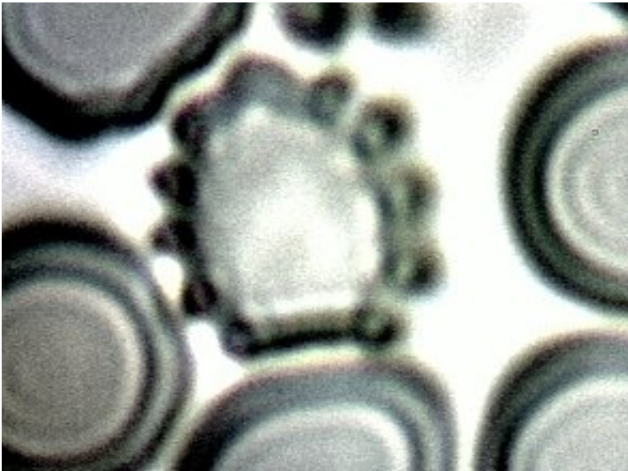The prelude to this paper is actually rooted within a series of previous papers that have been written over the last two decades. A few of these papers will be drawn from by example to set the stage for the recent threshold that has been crossed.

For those undesirous to follow this thread to its conclusions and propositions, it will be stated that the anomaly observed here is the alteration of blood in a combined biological and geometric sense; the end result of which remains uncertain. Those that continue to read will see the line of evidence, progression, and logic for themselves. One will then be in a better position to form their own opinion as to the significance of the events that are unfolding here.

The first paper that we should become familiar with was written via Carnicom Institute in 2009, approximately 10 years ago. This paper was titled, “A Mechanism of Blood Damage”, and it introduces the situation that we must now face, more directly, a decade later. A couple of relevant quotes and image follow:

“An organism and a method that damages the condition of the blood has now been identified and it has been directly observed. The blood variations reported here are in direct association with the existence of and the severity of the so-called “Morgellons” condition.”

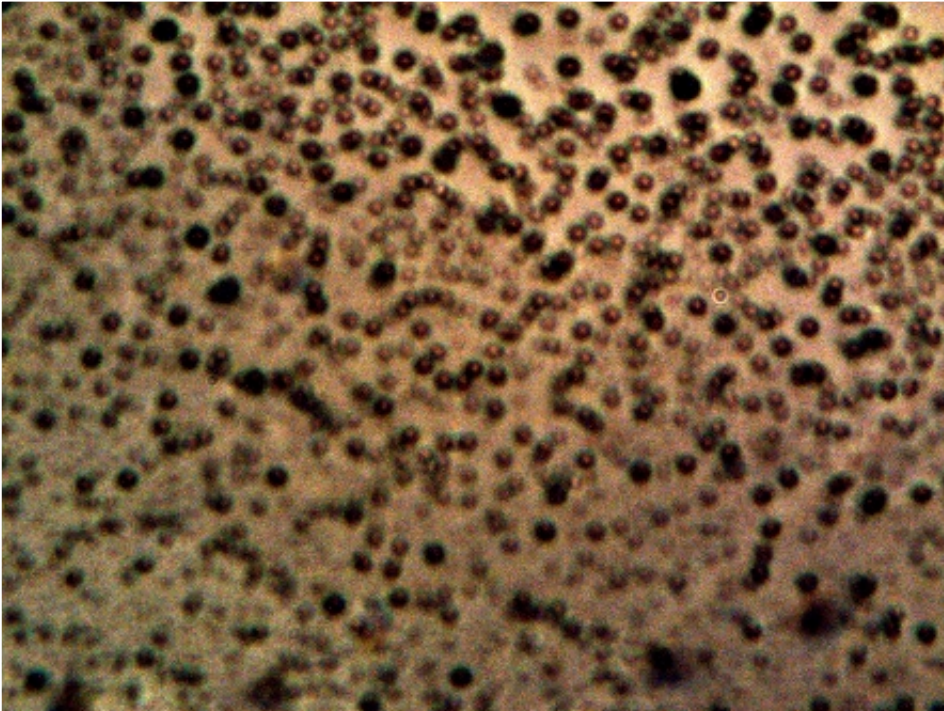
“...statistically it would certainly appear as though the general population is subject to these forms.”



From an early report in 2009 by Carnicom Insitute, titled “A Mechanism of Blood Damage”. This paper first presented the known impact of the Cross-Domain Bacteria (CDB)[tentative nomenclature] upon human blood.

Another relevant paper that could certainly be mentioned here is titled, “Cross-Domain Bacteria Isolation”, written in May of 2014. This paper introduces the tentative “Cross-Domain Bacteria” (CDB) nomenclature in response to the protracted abstention, avoidance and neglect of the scientific, medical, and goverment communities in spite of repeated and sustained presentation of important microbiological discoveries. The following quotation and photograph serve as an introduction to this paper”

"A sufficient time period has elapsed to allow for the identification, classification and designation of a novel and ubiquitous life-form that is known to exist in association with the so-called "Morgellons" condition. This call has thus far gone unheeded within the scientific community and more rapid progress is required. It has been stated, by discovery (ref. [The New Biology](#) Jan 2014), that this informal nomenclature is no longer sufficient to characterize the situation; that of an extensive, repeating and culturable life form with known properties and characteristics. "



Any papers that are discussed here need not be in chronological order, as there remains a continuous overlap between all research topics presented on this site over the last twenty years.

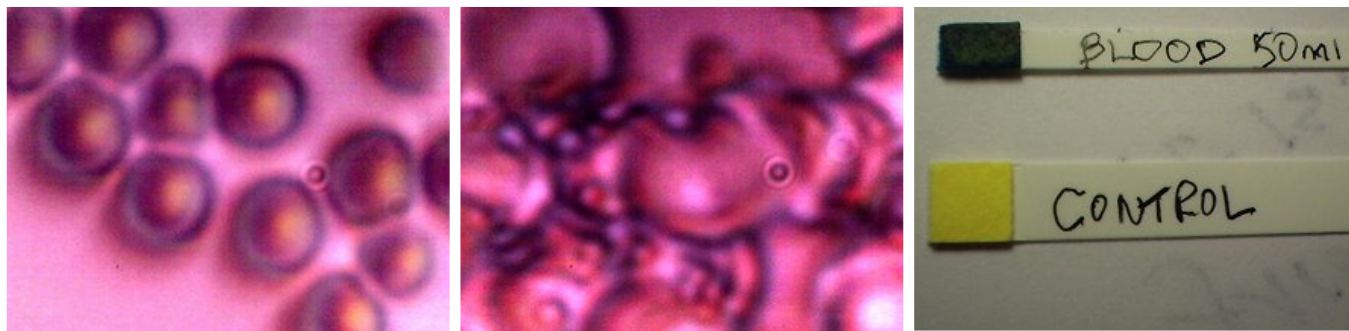
However strange it may have seemed at the time that they were written, the next pair of papers introduced the prospect of modified or artificial blood existing within certain cultures that had been developed. Several papers were written on the topic, and it is fair to say they raised the ire of certain interest groups and concerted efforts to dismiss the work were made. The work of the Institute is governed largely by the standard of repeatability, and therefore in the face of such skepticism, the blood work was repeated, repeated, and then repeated. The work stands as written.

While the notion of "artificial blood" may have seemed to be outside the norm of possibility for many of us at the time, the passage of time has shown us that the norms of biology have certainly changed dramatically over the last decade. Artificial blood research (with special emphasis upon military needs) was published publicly shortly after these papers were written. Anyone that is prone to think of biology, and artificial biology at that, need only look at the relatively recent introduction of CRISPR gene technology to show how quickly the world is changing.

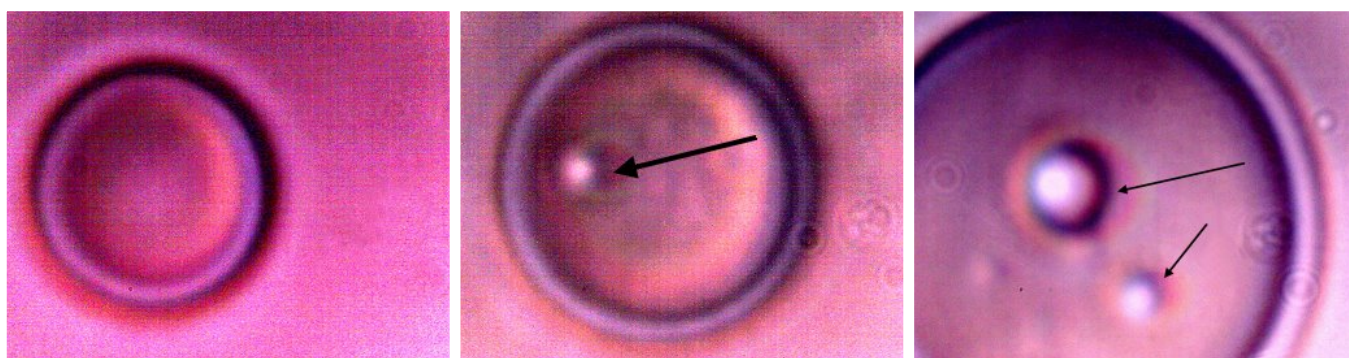
Two papers that can serve as examples for this phase of the research are:

1. Blood Issues Intensify (April 2009)
2. Artificial Blood (August 2009)

A few representative images to promote curiosity are presented below. They represent some of the unexpected culture trial results of the time, along with subsequent hemoglobin testing that took place. The microscope equipment at the time was relatively young in development at the time, but all work is distinctive, unique, and repeatable to the point of need. The second paper shows significant quality improvements with microscopy equipment and techniques. Readers should also pay attention to the unmistakable presence of the CDB in blood samples either examined or cultured, also well over 10 years ago.



Culture work and Hemoglobin Tests from the Paper “Blood Issues Intensify”, Apr 2009. Magnification approx. 3000x.

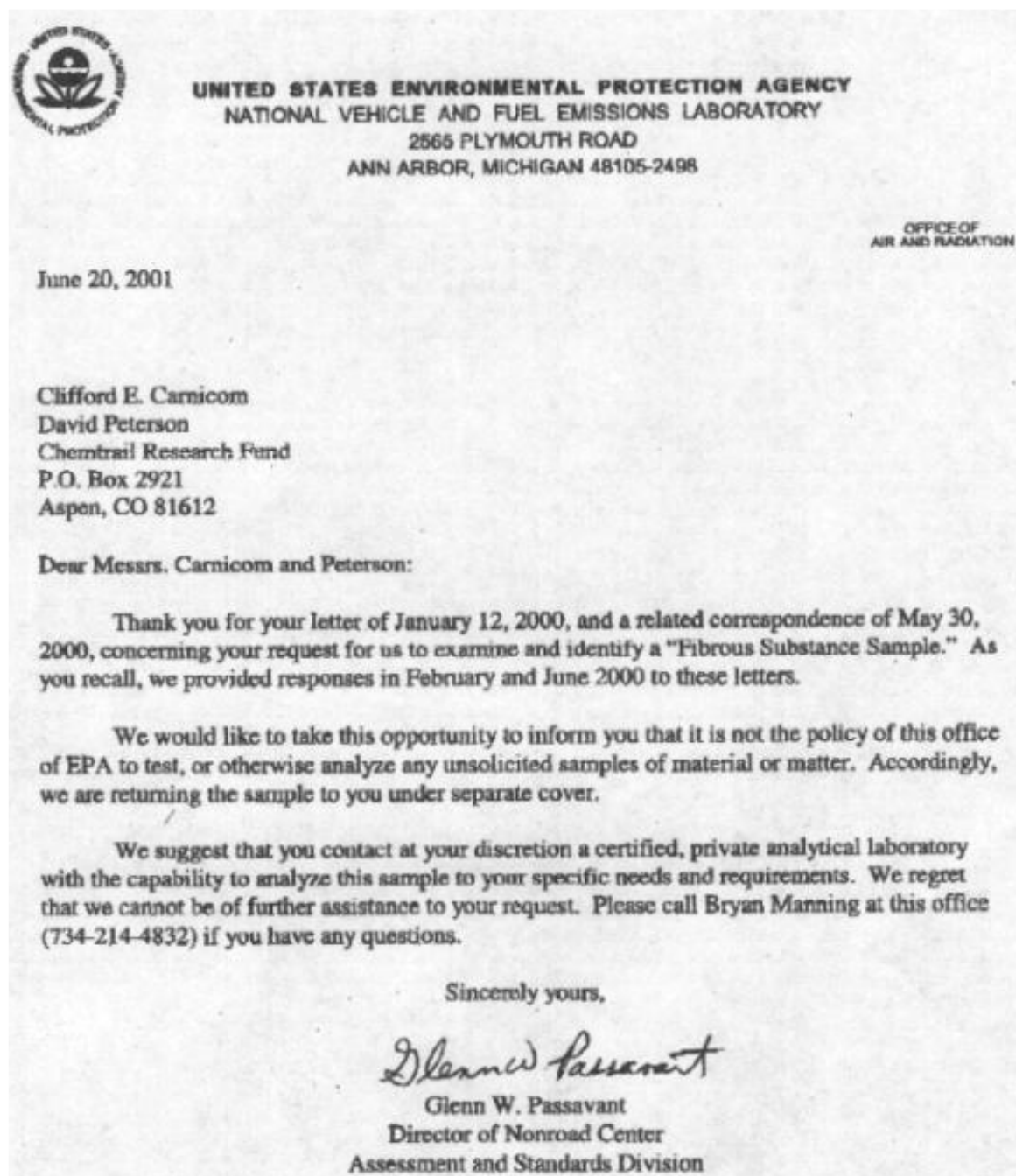


Unique erythrocytic (blood) and CDB culture work by Carnicom Institute in 2009. Magnification approx. 8000 – 10000x.

Before we go further, let’s address the question of “where”. Where does this unusual and specific microbe exist and come from?

The answer, at this point is “environmental”. It now exists in the general environment, at a global level, in any and all physical samples that have been examined. The include air, water, soil, and food as first examples. Any strategies or thought of hiding from, denying, avoiding, or refusing to acknowledge the omnipresent existence of this specific microbe appear to be in folly and vain at this point. “Elimination” of the microbe also would appear to be a fruitless enterprise. It is here, and nothing foreseeable shows that it will disappear. Our world is full of microbes; some neutral, some harmful and some benign. Not everyone is affected in the same way under the influence of various microbes, even those that have been identified as harmful. These statements should be kept in perspective as we , as a species, continue to sort out our relationship with this particular microbe. The earth and life are not static entities, and adaptability to changing circumstances are a hallmark of survival of a species. That is no different here.

All that being said, beyond the question of where it exists, is, where does or did it come from? This is a fair game question, however unpleasant that answer may be. The known evidence is this: the first identified source of this particular microbe is traced to an unusual airborne filament sample, with first examinations taking place in 1999. The United States Environmental Protection Agency was involved in those early discoveries, and the response of that agency can be found here:



EPA Refuses to Identify Sample (Jun 2000)

This researcher regards the EPA response as legally actionable for more than two decades, however no known legal challenge to the EPA's stated position has been put forth. Carnicom Institute has made its criticism of the EPA decision known for this same twenty year period, and the state of public health continues to be affected by that decision to this day. This microbe now is broadly distributed across the

full spectrum of the global environment.

It is also appropriate to make mention of a paper titled, “Morgellons : An Enviromental Source”, written in December of 2009. This was the first of many papers to follow that established the claim that the origin of the CDB was indeed environmental and of filament association. Although the microscopy at the time was relatively modest, the paper made justifiable basis to this claim that has only been verified in a continous sense since. As stated at the time,

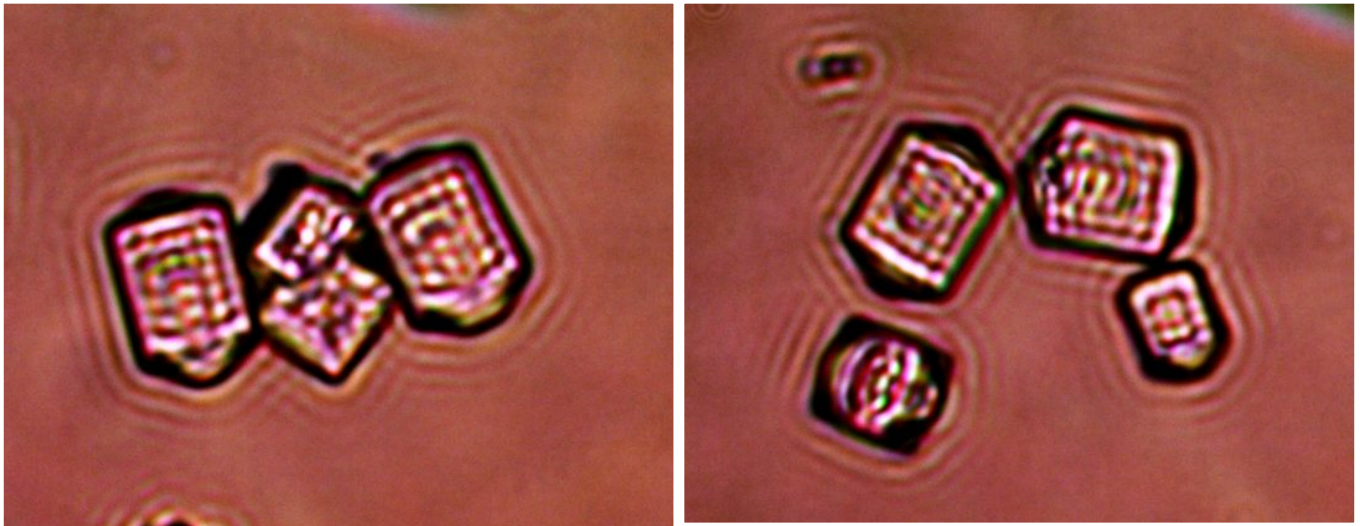
“An environmental source, at least in part, for specific biological organisms that are under scrutiny in association with the so-called “Morgellons” condition, has been identified. This source is the unusual airborne filament sample that was sent in June of 2000 to the Administrator of the United States Environmental Protection Agency (EPA) for identification on behalf of the public welfare. The United States EPA refused to acknowledge the existence of the sample for a period of one and one-half years, and subsequently returned the sample without identification after a Freedom of Information Act request for accounting was submitted by a third party.”

“This particular and same sample that was sent to the EPA has been successfully cultured and reproduced, and the culture growth exhibits the identical biological organisms, structure and chemistry of certain biological filaments that are under extensive study in association with the *Morgellons* condition. ”

Although a score or more of research papers relevant to the previous discussion could easily be presented, let us now advance to a more recent, and enigmatic, threshold of discovery. This is the subject matter of a much more recent paper titled, “Complex Observations, Unknown Consequence”, written in July of 2019. Once again, the photographs under the microscope are the evidence that we must consider. In this partcular case, the sample under observation was that of urine incubated under refrigeration for an extended period. Once again, a couple of quotations and photographs are presented to open up the new territory that is now before us:

“Significant, highly significant “geometric” development and formation involving the CDB microbe is most definitely on display here. Such observations at this level of uniqueness have never before been witnessed or recorded by this researcher in the two decades of research that precedes it.”


“There are obviously some important questions to ask here. One of these most certainly involves investigating the ‘driving force’, or cause of geometry now being introduced into the extensive microbial study that has brought us to this point. It is certainly warranted to open the discussion as to whether or not a biological ‘circuit’ or ‘network’ is established here. The distinction between nature and artificial design has certainly been presented to us, whether we welcome the prospect or not.”



Microphotograph of remarkable geometric “Cross-Domain Bacteria” (CDB) arrangement and development within an incubated urine sample. This represents the revelation of “ordered” structure of the CDB (“Cross-Domain Bacteria”) microbe that is known to be causal to the Morgellons condition. Each small sphere visible is a single CDB microbe that is approx. 0.3 microns in diameter. The period of incubation for the urine sample is approx. 6 months. Approx. magnification is 8000x

Although there is a long list of papers that will substantiate the progression of evidence presented here, we are now in a position to examine a more contemporary, but nevertheless related set of events. These events involve human blood and, once again, the issue returns closer to home.

We must now look at another extraordinary development, and that is the alteration of the fundamental morphology and geometry of red blood cells (erythrocytes) by the CDB microbe. It is now to be understood and accepted that Carnicom Institute puts forth the claim that the specific microbe under study here is causal to what has become known as the Morgellons health condition.



Microscopic images of anomalous human blood. Erythrocytes are infused with Cross-Domain Bacteria (CDB – tentative nomenclature). Cell membranes remain intact. Original magnification with photo to left is approx. 4000x. Digital magnification with photograph on right. Organized, structured, and packed CDB within the blood is evident. A comparison of these images with the anomalous urine samples above is appropriate.

It should also be known, at this time, that the images above are extraordinary and are restricted, at this level of development, to come from a single individual. However, as a complement to this statement, the blood of every individual does exhibit some degree of variation that is caused by the presence of the CDB. The case shown here appears to represent a more uniform and sophisticated evolution of changes that are now known to occur within human blood. The fact that the cell membranes are intact and that no material structural damage to the cells is evident is a remarkable event in its own right. Additional comments will be made on this fact later in this discussion, as this is known to not always be the case. In fact, it is known that structural damage to the cellular integrity is a much more common occurrence. At this time, there is only one individual known that has exhibited, AT THE LEVEL SHOWN, the change in human blood shown above. The data set remains incomplete. How many individuals are affected, to the above degree, remains unknown at this time. The changes are, however, scientifically valuable enough to warrant this disclosure.

Fortunately, although the data set is limited, there are some comparisons that can be made with other individuals. The blood of approximately a half dozen additional individuals has been observed under similar conditions and equipment to the case shown above. What is found that a “*gradation*” of CDB influence occurs within the other individuals. This ranges, therefore, from that of limited presence of the CDB to that of blood that shows serious compromise to the red blood cellular integrity. Examples of the extreme ends of the ranges that have been observed will be shown below. All individuals show some influence of the CDB presence, and this has been the case since initial blood observations were made years ago.

Before additional ‘control’ samples are introduced, let us state again that a unique attribute of the blood sample above is that the cell geometry remains in apparent integrity, and that the cell membranes do not show serious degradation as has been commonly observed over time.




Photo 1: Male, approx. 65 years

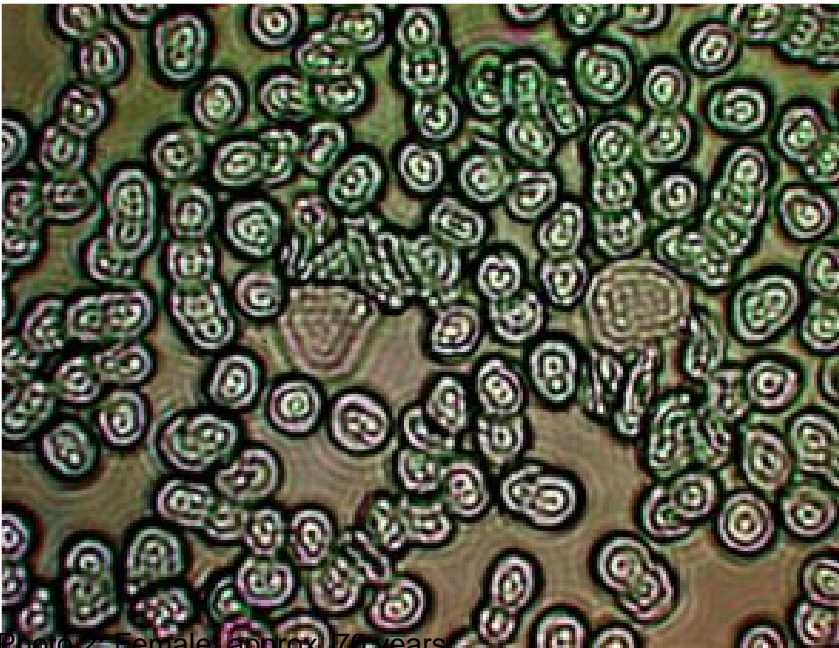


Photo 2: Female, approx. 70 years

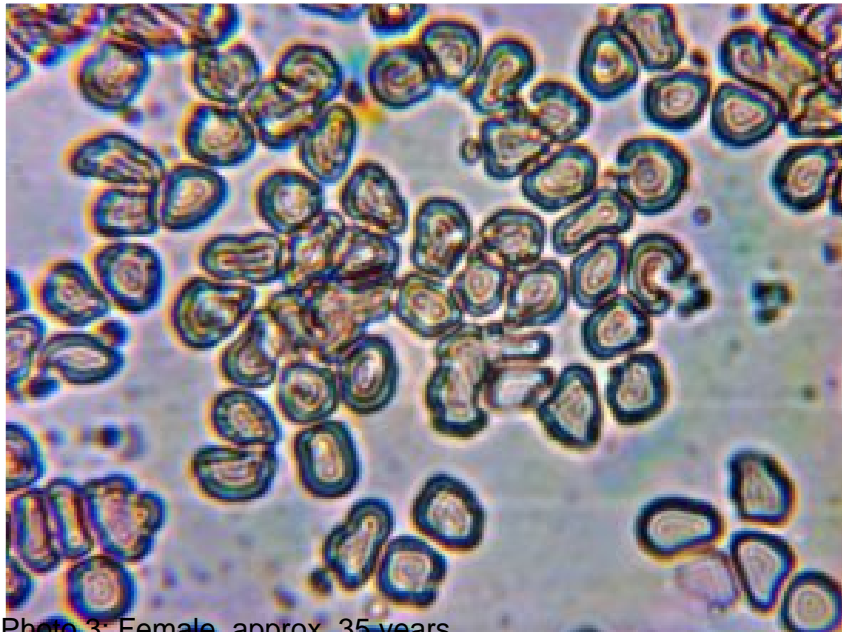


Photo 3: Female, approx. 35 years

Additional random samples of relatively recent blood observations
 Extended discussion below

A few comments are in order here, as we are fortunate to have a few “control” cases that we can make comparisons with. First, these photos are not selective; they can be regarded as a random sample of the population. No observations of individuals without some degree of CBD infusion are available at this time.

It can be seen that all individuals, at least to some degree, are subject to the phenomenon of CBD infusion and packing. Although remarkable in its own right, this finding is also consistent with that prepared from random samplings of the population many years ago. We may also infer, at least from the limited sample above, that age or sex do not appear to be primary variables that affect the degree of CBD infusion within the blood.

Let us discuss each case in somewhat more detail. Photo 1 is an interesting case in that it represents the least impact from the CBD in the cases shown. We also see that a higher age of the individual also does not necessarily correspond to the degree of CBD infusion shown. It is known that this individual is extremely selective and disciplined with respect to diet. I think that it can be fairly stated that this individual has devoted a great deal of attention to quality of diet and nutrition over an extended period of time. Certainly a highly disciplined and healthful diet is to be considered as a factor in any future studies of this type. We also acknowledge, however, that such devoted efforts do not, in this case, entirely prevent the intrusion or infusion of CBD within the blood cells.

It is also known that the individual of Photo 2 is also quite selective with respect to diet; although likely to a lesser degree than that from Photo 1. In this case we do see extensive CBD infusion. We also notice the cell membranes remain generally intact, although the circular geometry of the cells appears to be more disturbed than that from Photo 1. We also notice the presence of a couple of white blood cells (larger) that are heavily infused with the CBD, presumably in an attempt to remove the extensive microbe population from the blood.

Photo 3 demonstrates age is not necessarily any barrier to the onset of CBD infusion. One may examine

this issue more deeply with the past research paper titled “And Now Our Children” (Jan, 2008) on this site. What is noticed in this case is a higher level of CDB infusion along with a greater deterioration in the blood cell membrane integrity. No information on the dietary or life style attributes are known in the case.

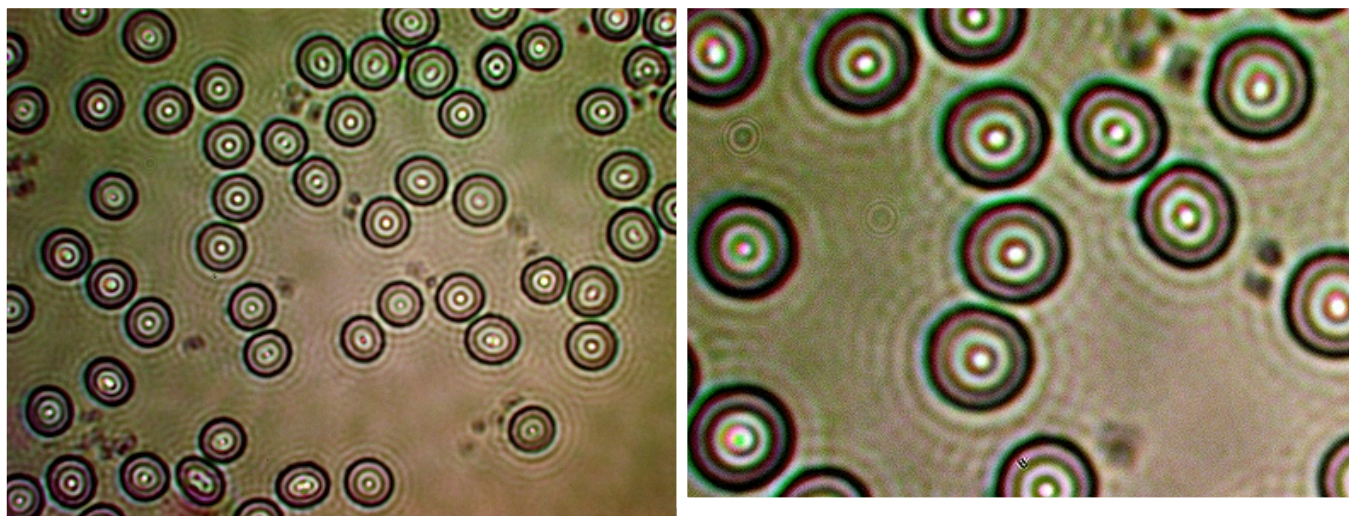
As we approach the tail of disclosure of important blood changes within the general population, there remains an additional intriguing chapter to report. The “transformation”, or changes that are underway, continue to evolve in unexpected and unknown ways, and with unknown consequences to human life.

The individual blood sample that has been highlighted within this report continues to show significant and anomalous changes within the blood.

There is, fortunately, a rather long history of blood observations for this individual, and at one time the damage shown was as severe as any that has ever been shown on this site. The reasons for the various changes that have taken place over the years, generally in the direction of improving cellular integrity, are likely involved and dependent upon the research of Carnicom Institute over the years. The latest disclosures, however, represent a most profound change in the state of affairs. The ante has now been raised, and it already was extraordinarily high.

Here is the most current situation:

Approximately three months after the blood observations of this report were made, a more recent set has been collected. Change has continued to take place, and the current status is shown below:



Recent blood observations from the individual previously exhibiting uniform and dense CDB infusion. The blood remains abnormal with the presence of the central “bulls eye” effect. The presence of a centralized CDB within the cells exists as a strong possibility. There has been previous observations over the years of this nature; what is distinct here is the uniformity of presence within each erythrocyte and the continued integrity of the cell membrane within a sustained anomalous CDB infusion state. The blood conditions of thalassemia (hereditary), codocytes, and macrocytes do not seem to apply in this case; all evidence points to the CDB as the source of the blood change. Hemoglobin tests in the past for this individual have produced normal results. Original magnification is approx 8000x; detail image to right.

In summary:

1. All blood samples examined visually over the course of existence of Carnicom Institute or related

research has shown the presence, at least to some detectable degree, of the Cross-Domain Bacteria (CDB – tentative nomenclature). The degree of impact to the cell integrity, and consequently to the human species, varies from less to severe.

2. Carnicom Institute makes the claim that the CDB are causal to the health condition that has assumed the name of “Morgellons” by the general public. No formal acceptance of the reality of this health condition by the general scientific or medical communities currently exists.

3. States of blood examined show frequent changes to cell morphology and integrity; this change appears to result primarily from the presence of the CDB within the blood.

4. CDB infusion within the cells can reach remarkable levels. The infusion impact spans a wide range of impact, from that of severe cellular damage to that of orderly and geometric arrangement. An amazing combination of massive geometric CDB infusion coupled with no detectable impact upon cellular integrity has now been observed and recorded.

5. The statistically significant presence and distribution of the CDB amongst the population observed, the sustained length of the observation period, and the phenomenal changes that are recorded herein force us to consider new boundaries on the state of human existence, cellular networking, and genetics.

6. The cultures, biological molecules and DNA of this specific microbe can be produced as a result of the research of Carnicom Institute. Primary answers exist within the DNA of this species. There need not be any ambiguity on these affairs, and the means to resolve certain problems and answer important questions on the observations shown here does exist.

7. There is no particular benefit to extrapolating the demonstrated scientific accomplishments to the point of unwarranted conjecture or claims. The substance of what is known about the microbe is sufficient to establish the further required campaign of discovery. Our work is now cut out before us, and any delay, avoidance, or denial will only compound the uncertainties that remain.

May God help us all.

Clifford E Carnicom
Born Clifford Bruce Stewart, Jan 19 1953

Thanksgiving Day
Nov 26, 2019